

Medical Chronology/Summary

Confidential and privileged information

Usage guideline/Instructions

***Verbatim summary:** All the medical details have been included “word by word” or “as it is” from the provided medical records to avoid alteration of the meaning and to maintain the validity of the medical records. The sentence available in the medical record will be taken as it is without any changes to the tense.

***Case synopsis/Flow of events:** For ease of reference and to know the glimpse of the case, we have provided a brief summary including the significant case details.

***Injury report:** Injury report outlining the significant medical events/injuries is provided which will give a general picture of the case.

***Comments:** We have included comments for any noteworthy communications, contradictory information, discrepancies, misinterpretation, missing records, clarifications, etc for your notification and understanding. The comments will appear in red italics as follows:
“**Comments*”.

***Indecipherable notes/date:** Illegible and missing dates are presented as “00/00/0000” (mm/dd/yyyy format). Illegible handwritten notes are left as a blank space “_____” with a note as “*Illegible Notes*” in heading reference.

***Patient’s History:** Pre-existing history of the patient has been included in the history section.

***Snapshot inclusion:** If the provider name is not decipherable, then the snapshot of the signature is included. Snapshots of significant examinations and pictorial representation have been included for reference.

***De-Duplication:** Duplicate records and repetitive details have been excluded.

General Instructions:

- *The medical summary focuses on Baby XXXX’s birth injuries and clinical condition, and treatments rendered for the developmental delays.*
- *All the records from 09/16/YYYY till 10/03/YYYY have been presented in detailed manner*
- *Further follow up visits focusing on the developmental delay and associated signs/symptoms were presented in details to show the resultant injuries sustained.*

Flow of events**XXXX Hospital:**

09/16/YYYY- 09/17/YYYY: Baby delivered via Augmented vaginal delivery for late decels with 18 hours of AROM - Infant complications included decreased variability, multiple late decels, meconium - Apgars 2 at 1 minute, 7 at 5 minute – Birth weight 3165 gm - Baby presented floppy with no respiratory efforts - Intubated and trachea suctioned – Transferred to Newborn Nursery at 1600 hours and started on antibiotics – Cord blood gas were 7.2/56/11/22/-6 - Noted with grunting at 1700 hours – Pulse ox decreased to 90% with increased grunting at 2115 hours and started on supplemental O2 – Initial blood culture was positive for E. coli – Started on Oxyhood 40% at 0100 hours on 09/17/YYYY – Noted with increased respiratory distress with tachypnea and become hypoxic with grunting, with mild retractions – Transferred to XXXX Hospital NICU at 0335 hours

**XXXX Hospital:**

09/17/YYYY – 10/03/YYYY: Infant presented with moaning/grunting, noises, arms and legs in bicycling motion (able to stop with soft pressure) however continuous motion, barrel chest and scaphoid abdomen (no bowel sounds heard in chest) – Diagnosed with severe respiratory distress with metabolic acidosis, sepsis and abnormal neurologic findings on admission – intubated and UVC placed – Neurology consulted and assessed with very abnormal EEG showing suppression of activity and seizure activity but not status epilepticus; Started on Phenobarbital – Ultrasound of head was normal – CT of head on 09/18/YYYY revealed diffuse hypodensity of both cerebral hemispheres and posterior fossa strongly suggests diffuse cerebral edema and global anoxic or hypoxic encephalopathy – On 09/21/YYYY, feeding evaluation revealed Oral dysphagia and feeding difficulty – MRI of brain on 09/21/YYYY revealed a tiny area of blooming on the gradient echo sequence in the left parietal lobe representing punctate hemorrhage or calcification and posterior scalp swelling/hematoma – Infant was assessed with acute anoxic encephalopathy – EEG on 09/25/YYYY revealed findings suggestive of diffuse cortical injury – On 10/03/YYYY, baby was discharged home – Discharge assessment included weight 3348 grams, very jerking movements and mild tremors and placed on Enficare ad lib

**XXXX Medicine – Queen**

10/05/YYYY: Presented for follow up – He was on Formula- Enfamil newborn – Weight 7 lbs 9 oz – He was referred to outpatient speech, neurodevelopmental clinic and Early Intervention Services



10/07/YYYY: Speech therapy evaluation for oral dysphagia – He was assessed with mild oral dysphagia characterized by diminishing lingual cupping with nutritive Suck on a Nuk orthodontic nipple – Recommended therapy for 6 times within a 12-week period with a speech therapist to address oral motor deficits and to determine an adequate feeding plan

**XXXX Hospital**

10/22/YYYY: ER visit for runny nose – Recommended to use bulb syringe to suction nasal secretion

**XXXX Neurology – Peds**

10/22/YYYY: Neurodevelopmental followup visit – Muscle tone was normal - There was no abnormal posturing on vertical or ventral suspension - Recommended to continue with Early Intervention services



XXXX Hospital

11/10/YYYY: ER visit for feeding difficulty, diarrhea and frequent cry – Assessed with Failure to thrive – Admitted for Feeding evaluation – Speech therapy evaluation performed on 11/11/YYYY and assessed with mild oral dysphagia with diminished lingual cupping and recommended therapy for 4 times per week for 2 weeks – Ultrasound on 11/11/YYYY revealed periventricular leukomalacia likely due to early ischemic change – Discharged on 11/12/YYYY with plan for home nursing visits and pediatrician follow up – Enfamil formula 3-4 ounces every 3-4 hours was ordered for nutrition



XXXX Rehabilitation

12/01/YYYY: Discharged from Speech Therapy secondary to difficulty attending appointments in a timely fashion and overall increase of cancels and no shows – Infant continued to exhibit a mild oral dysphagia characterized by diminishing lingual cupping



XXXX Hospital

12/14/YYYY-12/19/YYYY: Admitted on 12/14/YYYY for evaluation of failure to thrive and to rule out seizures – It was reported that he was demonstrating some posturing over the last 2-3 weeks; extension of the arms and flexion of the elbows with hands at the head and flexion of the hips and knees with episode lasting for 1-2 minutes – Neurology was consulted and assessed with abnormal motor activity and irritability – EEG revealed suppression of normal cortical rhythms bilaterally over the central, parietal, temporal and occipital regions – He was started on Gabapentin – CT of head performed on 12/15/YYYY and it revealed extensive bilateral cerebral atrophy with associated deformity of the calvaria – CT skull with 3D reconstruction revealed overlapping sutures, with some foci of fusion, likely secondary to extensive bilateral cerebral atrophy rather than primary craniosynostosis – On 12/19/YYYY, he was discharged to home on Gabapentin and follow up instructions



XXXX Pediatric Medicine – Queen

01/08/YYYY: Office visit to establish care – Assessed with Specific delays in development, Plagiocephaly – Vaccination administered and referred to Early Intervention Services



XXXX Neurology – Peds

01/11/YYYY: Neurology follow up visit – He appeared more relaxed while on Gabapentin – Advised to consult Neurosurgery and to continue Early Intervention



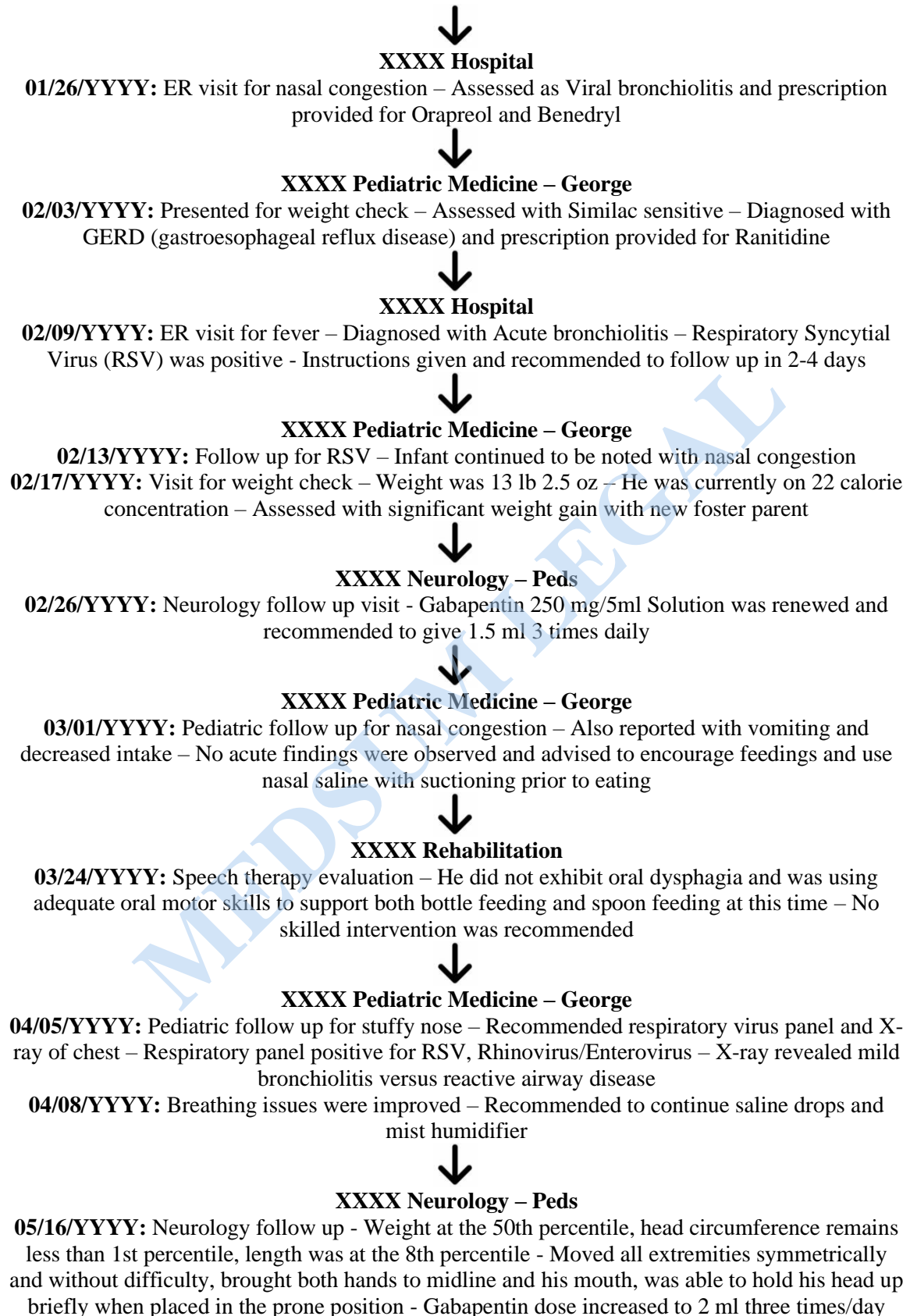
XXXX Neurosurgery – York

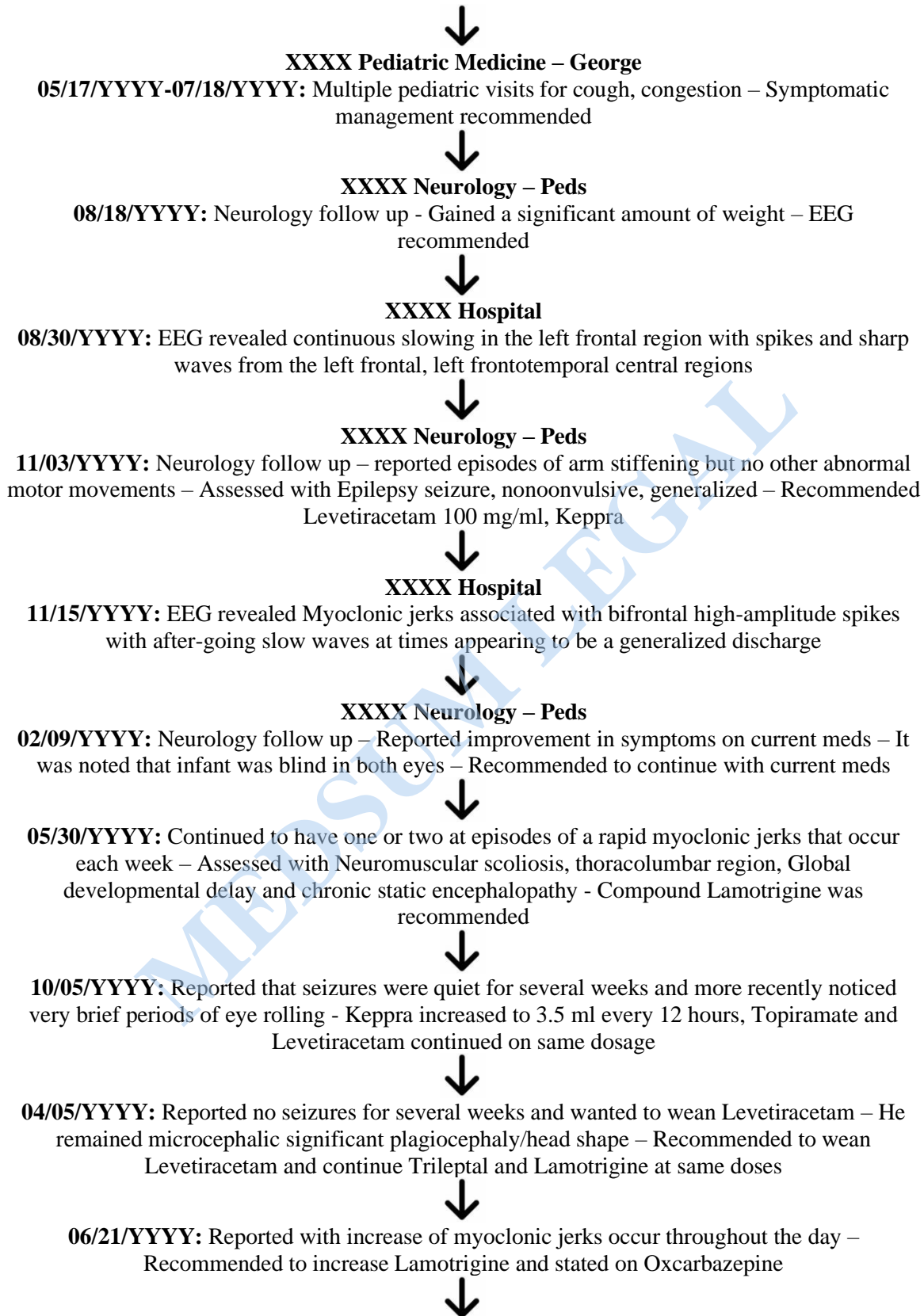
01/14/YYYY: Presented with concerns of head shape and suture premature closure – Stated that no surgical remedy for the brain loss incurred and secondary calvarial misshapen position



XXXX Pediatric Medicine – George

01/19/YYYY: 4 month well child visit – Assessed with behind on immunizations and specific delays in development





Patient Name

DOB: MM/DD/YYYY

08/29/YYYY: Myoclonic jerks decreased reported to have more than he used to get several months ago – Assessed with Intractable epilepsy with both generalized and focal features - Increased the Lamotrigine to 37.5 mg twice daily and to continue 250 mg of Levetiracetam twice daily



XXXX Pediatric Medicine – George

09/19/YYYY-10/19/YYYY: Multiple visits for well child visit, respiratory complaints, mouth sore, bump on eye, and vomiting – Symptomatically managed



12/11/YYYY: Continued to have multiple seizures on a daily basis – Suggested to start him on Epidiolex/Cannabadiol

Maternal History

Past Medical History: Unknown

Social History: No history of smoking, or substance usage (Bates Ref: MH-264-AH)

Allergy: No latex allergies (Bates Ref: MH-264-AH)

Detailed Summary

DATE	FACILITY/ PROVIDER	MEDICAL EVENTS	BATES REF
<i>XXXX Hospital (09/16/YYYY – 09/17/YYYY)</i>			
09/16/YYYY	Provider/Hospital Name	<p>Delivery attendance note: <i>(Illegible Notes)</i></p> <p>Intervention: Stimulation, positive pressure ventilation, CPAP Details: I was called to this vaginal delivery for ___ and ___. Mother is a 18-year-old G1, 39 weeks of gestation. Maternal labs were normal with adequate ___. Augmented vaginal delivery for late decels with 18 hours of AROM with ___. Mother spiked a temp before delivery.</p> <p>Apgars: 2 at 1 minute, 7 at 5 minute</p> <p>Post-delivery assessment/evaluation: Baby presented floppy with no respiratory efforts. He was intubated and trachea suctioned with no ___ below the cords. He was then started on PPV using BMV ___ for about 2 minutes before started breathing. He was then started on CPAP and continued for another 2 minutes. Baby was tachycardia from the beginning, tone gradually improved. Apgar score 2 and 7 at 1 and 5 minutes. Cord blood gas: 7.2-56/11/22/-6. Rectal temp was 102.</p> <p>Recommendations: Will repeat arterial blood gas Obtain a CBC and blood culture</p>	MH-129-CLT

DATE	FACILITY/ PROVIDER	MEDICAL EVENTS	BATES REF
		Will start antibiotics Departure status: Newborn Nursery	
09/16/YYYY	Provider/Hospital Name	<p>@1559 hours: Cord blood analysis:</p> <p>Arterial cord blood gas: pH 7.198, pCO2 56.2, pO2 11, base excess -6, HCO3 21.9, tCO2 24, sO2 7%</p> <p>Cord ABO/Rh – B positive</p>	MH-283-AH, MH-163-CLT
09/16/YYYY	Provider/Hospital Name	<p>@1600 hours: Admission information:</p> <p>Admitted from: Labor and delivery room Weight: 3165 gm Length: 53.4 cm Head circumference: 31.50 cm Chest circumference: 31.0 cm</p> <p>Environment: Radiant warmer Vitals: Temp 102.9, heart rate 180, resp. rate 42, room air Skin: Intact, pink, elastic Head/neck: Caput succedaneum Face: Symmetric appearance, facial movement symmetrical Neck: Symmetrical, full range of motion Eyes: Symmetrically placed, sclera clear Ears: Symmetrical, cartilage well formed Nose: Symmetrical, patent bilateral, midline position Mouth: Symmetrical, palate, lips, tongue, mucous membrane intact gums pink Sutures: Separated Fontanelles: Soft, flat Chest/cardiovascular: Symmetric thorax, intact clavicles, strong regular heart sounds Lungs: Normal spontaneous respiration, bilateral crackles present Abdomen: Soft, rounded abdomen, white moist cord, 2 arteries and 1 vein cord vessels Musculoskeletal: Intact spine, normal hips, full range of motion, symmetrical gluteal folds Pelvis: Normal male genitalia, both testes descended Neuromuscular: Flaccid tone, cry absent, activity – quiet alert, reflexes – cry, Moro, gag, suck, grasp, Babinski</p> <p>Cord care: Clamped</p> <p>Maternal Pregnancy/Delivery: EDC by date: 09/21/YYYY Delivery doctor: Anthony Piccolo, D.O.</p> <p>Infant delivery information: Delivery date: 09/16/YYYY, 1549 hours</p>	MH-262-AH- MH-266-AH, MH-274-AH- MH-276-AH

DATE	FACILITY/ PROVIDER	MEDICAL EVENTS	BATES REF
		Rupture of membrane: 09/15/YYYY, 2044 hours Method of delivery: Vaginal Suction: Mouth, nose, pharynx Amniotic fluid color: Light meconium Length of rupture: 19.08 Shoulder dystocia: No Presentation: Cephalic Cephalic position: Vertex Vertex position: Left occipital anterior Assessment: Respiration: Appears normal Physical findings: Caput succedaneum, bruising Infant complications: Decreased variability, multiple late decels, meconium Appgars: 2 at 1 min, 7 at 5 min	
09/16/YYYY	Provider/Hospital Name	@1640 hours: Nursing Notes: (Illegible Notes) Infant to NSY under heat shield with temp probe applied. Temp 36.8 by temp probe, pulse 156, resp. rate 68. Color pink. Infant grunting. No nasal flaring, no retracting. Lungs congested bilaterally. Pulse ox O2 sats 95-98%. IV capped line, attempted x 2 in left hand and in right hand with #24 gauge _____. IV capped infant probe.	MH-271-AH
09/16/YYYY	Provider/Hospital Name	@1644 hours: Assessment: Vitals: Temp 102.9 F, apical heart rate 180, resp. rate 42, room air Height: 53 cm Weight: 3.16 kg	MH-58-CLT-MH-60-CLT
09/16/YYYY	Provider/Hospital Name	@1700 hours: Nursing Notes: Infant remains on heat shield with temp probe attached. Axillary temp 98.6, axillary pulse ox is 90 on room air. Awaiting lab for blood cultures and CBC draw. Pulse 162, resp. rate 80.	MH-271-AH
09/16/YYYY	Provider/Hospital Name	@1700 hours: Nursing assessment: (Illegible Notes) Temp 98, pulse 162, resp. rate 80 Color pink Capillary refill <3 sec O2 mode – Room air O2 sats 92% Lung sounds Abnormal Retractions – No Nasal flaring – No Grunting – Yes LOC – A/L IV – _____	MH-270-AH

DATE	FACILITY/ PROVIDER	MEDICAL EVENTS	BATES REF
09/16/YYYY	Provider/Hospital Name	<p>@1730 hours: Nursing assessment:</p> <p>Pulse 156, resp. rate 70 Color pink Capillary refill <3 sec O2 mode – Room air O2 sats 93-95% Lung sounds Abnormal Retractions – Yes Nasal flaring – Yes Grunting – Yes LOC – A/L Glucose 51 IV – capped</p>	MH-270-AH
09/16/YYYY	Provider/Hospital Name	<p>@1800 hours: Nursing assessment:</p> <p>Pulse 156, resp. rate 84 Color pink Capillary refill <3 sec O2 mode – Room air O2 sats 95% Lung sounds Abnormal Retractions – Yes Nasal flaring – Yes Grunting – Yes LOC – A/L Glucose 51 IV – capped</p>	MH-270-AH, MH-276-AH- MH-277-AH
09/16/YYYY	Provider/Hospital Name	<p>@1818 hours: X-ray of chest:</p> <p>Reason for exam: Respiratory distress, congestion</p> <p>Impression: No consolidation, congestion or pleural effusion</p>	MH-136-AH
09/16/YYYY	Provider/Hospital Name	<p>@1827 hours: Nursing Notes:</p> <p>Assumed care of patient in Nursery. Infant color pink. Tone hypotonic, lungs coarse with crackles bilaterally. No retractions or flaring. Blood culture taken/X-ray taken.</p>	MH-271-AH
09/16/YYYY	Provider/Hospital Name	<p>@1830 hours: Nursing assessment:</p> <p>Temp 37.0, pulse 162, resp. rate 87 Color pale Capillary refill <3 sec O2 mode – Room air O2 sats 97% Lung sounds Abnormal Retractions – No Nasal flaring – No</p>	MH-270-AH

DATE	FACILITY/ PROVIDER	MEDICAL EVENTS	BATES REF
		Grunting – No LOC – A/L IV – capped	
09/16/YYYY	Provider/Hospital Name	@1849 hours: Lab report: High: RDW 19.1	MH-140-AH
09/16/YYYY	Provider/Hospital Name	@1900 hours: Nursing assessment: Temp 98, pulse 159, resp. rate 92 Color pale Capillary refill <3 sec O2 mode – Room air O2 sats 98% Lung sounds Abnormal Retractions – No Nasal flaring – No Grunting – No LOC – A/L IV – Nil	MH-270-AH
09/16/YYYY	Provider/Hospital Name	@1930 hours: Nursing assessment: Temp 37.0, pulse 148, resp. rate 72 Color pale Capillary refill <3 sec O2 mode – Room air O2 sats 99% Lung sounds normal Retractions – Yes Nasal flaring – No Grunting – No LOC – A/L IV – Nil	MH-270-AH
09/16/YYYY	Provider/Hospital Name	@1930 hours: Lab report: Total bilirubin 2.0 (High)	MH-139-AH
09/16/YYYY	Provider/Hospital Name	@1931 hours: Newborn Admission Note: Maternal information: Labor and delivery anesthesia: Epidural Intrapartum maternal complication: Maternal fever Maternal Labs: Blood type: AB positive Group Beta Strep: Done 08/07/YYYY Rubella: Immune Gonorrhea, Chlamydia, Hepatitis B: Negative Infant admission measurement:	MH-232-AH- MH-234-AH

DATE	FACILITY/ PROVIDER	MEDICAL EVENTS	BATES REF
		<p>Birth weight: 3195 g (7 lbs 1 oz)</p> <p>Delivery attendance note: Reason for attending: Meconium</p> <p>Interventions: Stimulation, Positive Pressure Ventilation, CPAP Details: I was called to this vaginal delivery for MSP and NRFHT. Mother is a 18-year-old G1 at 39 weeks of gestation. Maternal labs normal with adequate PNC. Augmented vaginal delivery for late decels with 18 hours of AROM with MSF. Mother spiked a temp before delivery.</p> <p>Post Delivery Assessment/Evaluation: Baby presented floppy with no respiratory effort. He was intubated and trachea suctioned with no mec below the cords. He was then started on PPV using BMV and continued for about 2 minutes before he started breathing. He was then started on CPAP and continued for another 2 minutes. Baby was tachycardic from the beginning, tone gradually improved. Apgar scores 2 and 7 at 1 and 5 minutes, cord blood gas; 7.2/56/11/22/-6. Rectal temp was 102.9.</p> <p>Recommendations: Will repeat arterial blood gas Obtain a CBC and blood culture Will start antibiotics</p> <p>Departure Status: Newborn Nursery</p> <p>Physical examination: General Appearance: Within normal limits Skin: Within normal limits Neurological: Normal Tone, Moro, Grasp, Root, Suck Musculoskeletal: Within normal limits, full range of motion, spontaneous movement all extremities, intact clavicles, clavicles without crepitus, gluteal folds symmetrical, spine within normal limits, no sacral dimple/cyst Head: Normal fontanelles. normocephalic, sutures WNL EENT: Mouth within normal limits, ears within normal limits, eyes within normal limits, eyes red reflex bilaterally, nose within normal limits, face within normal limits. Cardiovascular: Within normal limits, normal pulse Respiratory: Tachypneic Gastrointestinal: Within normal limits, soft, normal liver, non palpable spleen, patent anus Umbilicus: Within normal limits, three vessel cord Additional Comments: Pulse ox 98%; Chest X-ray negative; resp. rate 80</p> <p>Impression: Vital Signs Appropriate, Bonding Appropriately,</p>	

DATE	FACILITY/ PROVIDER	MEDICAL EVENTS	BATES REF
		Voiding and Stooling Plan: Continue Newborn Care Additional Notes: TTN; will monitor respiratory rate; Antibiotics for fever.	
09/16/YYYY	Provider/Hospital Name	@1935 hours: Lab report: High: Monocyte 12, nucleated RBC 13 Low: Basophil 0	MH-139-AH
09/16/YYYY	Provider/Hospital Name	@2000 hours: Nursing assessment: Temp 37.0, pulse 149, resp. rate 82 Color pale Capillary refill <3 sec O2 mode – Room air O2 sats 97% Lung sounds normal Retractions – Yes Nasal flaring – No Grunting – No LOC – A/L IV – D10, Ampicillin	MH-270-AH
09/16/YYYY	Provider/Hospital Name	@2000 hours: Nursing Notes: New IV started into right mid forearm. Previous IV unusable; infiltrated with flush. D10% running at 10 ml/hr per physician. IV Ampicillin started at 2000 hours.	MH-271-AH
09/16/YYYY	Provider/Hospital Name	@2030 hours: Nursing assessment: Temp 37.0, pulse 157, resp. rate 60 Color pale Capillary refill <3 sec O2 mode – Room air O2 sats 91% Lung sounds normal Retractions – No Nasal flaring – No Grunting – No LOC – A/L IV – D10 10 ml/hr, Gentamicin	MH-270-AH
09/16/YYYY	Provider/Hospital Name	@2041 hours: Nursing Notes: IV Gentamicin 13 mg started.	MH-271-AH
09/16/YYYY	Provider/Hospital Name	@2100 hours: Nursing assessment: Temp 37.0, pulse 145, resp. rate 74 Color pale Capillary refill <3 sec	MH-270-AH

DATE	FACILITY/ PROVIDER	MEDICAL EVENTS	BATES REF
		O2 mode – Room air O2 sats 92% Lung sounds normal Retractions – No Nasal flaring – No Grunting – Yes LOC – A/A IV – D10 10 ml/hr	
09/16/YYYY	Provider/Hospital Name	@2115 hours: Nursing Notes: Baby pulse ox decreased to 90% with increased grunting. Started 2L O2 via nasal cannula. Pulse ox with supplemental O2 at 96%.	MH-271-AH
09/16/YYYY	Provider/Hospital Name	@2130 hours: Nursing assessment: Temp 37.0, pulse 159, resp. rate 66 Color pale Capillary refill <3 sec O2 mode – 1.5 L O2 sats 97% Lung sounds normal Retractions – No Nasal flaring – No Grunting – Yes LOC – A/A IV – D10 10 ml/hr	MH-270-AH
09/16/YYYY	Provider/Hospital Name	@2200 hours: Nursing assessment: Temp 36.9, pulse 155, resp. rate 61 Color pale Capillary refill <3 sec O2 mode – 1.5 L O2 sats 96% Lung sounds normal Retractions – No Nasal flaring – No Grunting – Yes LOC – A/A IV – D10 10 ml/hr	MH-270-AH
09/16/YYYY	Provider/Hospital Name	@2210 hours: Nursing Notes: Called Dr. Ventura to make aware of grunting and O2. Awaiting further direction form NICU.	MH-271-AH
09/16/YYYY	Provider/Hospital Name	@2215 hours: Nursing Progress Notes: Spoke with Dr. Ventura regarding MICU recommendations. Will continue to monitor newborn in nursery for 2 more hours, of nay change/decline in condition baby will likely be shipped to YH NICU. Will monitor newborn closely in nursery.	MH-258-AH

DATE	FACILITY/ PROVIDER	MEDICAL EVENTS	BATES REF
09/16/YYYY	Provider/Hospital Name	<p>@2230 hours: Nursing assessment:</p> <p>Temp 36.8, pulse 164, resp. rate 48 Color pale Capillary refill <3 sec O2 mode – 1.5 L O2 sats 95% Lung sounds normal Retractions – No Nasal flaring – No Grunting – Yes LOC – A/A IV – D10 10 ml/hr</p>	MH-270-AH
09/16/YYYY	Provider/Hospital Name	<p>@2300 hours: Nursing assessment:</p> <p>Temp 36.8, pulse 170, resp. rate 71 Color pale Capillary refill <3 sec O2 mode – 1.5 L O2 sats 95% Lung sounds normal Retractions – No Nasal flaring – No Grunting – Yes LOC – A/A IV – D10 10 ml/hr</p>	MH-270-AH
09/16/YYYY	Provider/Hospital Name	<p>@2330 hours: Nursing assessment:</p> <p>Temp 97.0, pulse 161, resp. rate 55 Color pale Capillary refill <3 sec O2 mode – 2L O2 sats 98% Lung sounds clear Retractions – No Nasal flaring – No Grunting – Yes LOC – A/A IV – D10 10 ml/hr</p>	MH-269-AH
09/16/YYYY	Provider/Hospital Name	<p>@2400 hours: Nursing assessment:</p> <p>Temp 37.1, pulse 149, resp. rate 41 Color pale Capillary refill <3 sec O2 mode – 2L O2 sats 98% Lung sounds clear Retractions – No</p>	MH-269-AH

Patient Name

DOB: MM/DD/YYYY

DATE	FACILITY/ PROVIDER	MEDICAL EVENTS	BATES REF
		Nasal flaring – No Grunting – Yes LOC – A/A IV – D10 10 ml/hr	
09/16/YYYY	Provider/Hospital Name	Blood culture and sensitivity report: (Illegible Notes) Collected date: 09/16/YYYY Aerobic pediatric ___ is positive Escherichia coli Escherichia coli susceptible to Amikacin, Cefazolin, Cefepime, Ceftriaxone, Ciprofloxacin, Gentamicin, Imipenem, Levofloxacin, Meropenem, Piperacillin/Tazobactam, tobramycin, Trimethoprim/Sulfa	MH-141-AH
09/17/YYYY	Provider/Hospital Name	@0015 hours: Nursing Progress Notes: (Illegible Notes) Placed call to Dr. Ventura regarding current status of nursery baby. Dr. Ventura stated that NICU is comfortable with newborn staying at our nursery if our staff is comfortable. Will keep baby and if condition deteriorates, will call back Dr. Ventura. Started baby under Oxyhood at 0030 hours for humidified oxygen. Oxygen blender at 36.6% inside hood. Saturations of baby pulse ox remain 96-97%. No further signs of distress noted. IV ___ at 10 ml/hr continues. Site without redness or signs of infiltration.	MH-258-AH
09/17/YYYY	Provider/Hospital Name	@0030 hours: Nursing assessment: (Illegible Notes) Temp 37.1, pulse 150, resp. rate 67 Color pale Capillary refill <3 sec O2 mode – 2L O2 sats 99% Lung sounds clear Retractions – No Nasal flaring – No Grunting – ___ LOC – A/L IV – D10 10 ml/hr	MH-269-AH
09/17/YYYY	Provider/Hospital Name	@0100 hours: Nursing assessment: Temp 36.9, pulse 163, resp. rate 69 Color pale Capillary refill <3 sec O2 mode – Oxyhood 40% O2 sats 97% Lung sounds normal Retractions – No Nasal flaring – No Grunting – Yes	MH-269-AH

DATE	FACILITY/ PROVIDER	MEDICAL EVENTS	BATES REF
		LOC – A/L IV – D10 10 ml/hr	
09/17/YYYY	Provider/Hospital Name	@0130 hours: Nursing assessment: Temp 36.9, pulse 179, resp. rate 65 Color pale Capillary refill <3 sec O2 mode – Oxyhood 50% O2 sats 98% Lung sounds normal Retractions – Mild Nasal flaring – No Grunting – Yes LOC – A/A IV – D10 10 ml/hr Void +1	MH-269-AH
09/17/YYYY	Provider/Hospital Name	@0200 hours: Nursing assessment: Temp 98.2, pulse 171, resp. rate 61 Color pale Capillary refill <3 sec O2 mode – Oxyhood 45% O2 sats 97% Lung sounds normal Retractions – Mild Nasal flaring – No Grunting – Yes LOC – A/A IV – D10 10 ml/hr	MH-269-AH
09/17/YYYY	Provider/Hospital Name	@0217 hours: Nursing Progress Notes: Spoke with Dr. Ventura regarding baby's decline in condition. Grunting constant now and Oxyhood has to continually be increased to maintain saturation > 94%. Baby likely to be transferred to NICU at YH.	MH-258-AH
09/17/YYYY	Provider/Hospital Name	@0230 hours: Nursing assessment: Temp 36.8, pulse 176, resp. rate 94 Color pale Capillary refill <3 sec O2 mode – Oxyhood 50% O2 sats 95% Lung sounds normal Retractions – Mild Nasal flaring – No Grunting – Yes LOC – A/A IV – D10 10 ml/hr	MH-269-AH

DATE	FACILITY/ PROVIDER	MEDICAL EVENTS	BATES REF
		Glucose 62	
09/17/YYYY	Provider/Hospital Name	@0230 hours: Nursing Progress Notes: Preparing for transfer to NICU for deterioration of respiratory status.	MH-258-AH
09/17/YYYY	Provider/Hospital Name	@0250 hours: Nursing assessment: Face – Symmetrical Appearance; Facial Movement Symmetrical Eyes - Symmetrical placed annotation; Eyes have never opened yet Ears – Symmetrical; cartilage well formed Thorax – Symmetrical barrel chest Lungs- tachypneic; grunting Breath sounds – Equal bilateral Retractions – None, 1+ mild Musculoskeletal – Moves all four extremities Neuromuscular – Hypotonic. Cry absent. Reflexes – grasp Communication – Awaiting a NICU transfer	MH-277-AH- MH-278-AH
09/17/YYYY	Provider/Hospital Name	@0300 hours: Nursing assessment: Temp 36.9, pulse 182, resp. rate 94 Color pale Capillary refill <3 sec O2 mode – Oxyhood 45% O2 sats 95% Lung sounds normal Retractions – Mild Nasal flaring – No Grunting – Yes LOC – A/A IV – D10 10 ml/hr	MH-269-AH
09/17/YYYY	Provider/Hospital Name	@0315 hours: Nursing Progress Notes: NICU transport team arrived to transport baby. Baby immediately put on CPAP and prepared for transport.	MH-258-AH
09/17/YYYY	Provider/Hospital Name	@0335 hours: Transfer Report: Receiving facility: NICU – XXXX Hospital	MH-54-CLT- MH-55-CLT
09/17/YYYY	Provider/Hospital Name	@0400 hours: Nursing Progress Notes: NICU transport team leaves unit with newborn. Newborn stabilized for transport.	MH-259-AH
09/17/YYYY	Provider/Hospital Name	Newborn Discharge Note: Comments: Patient transferred after midnight last night. YH NICU contacted at 2209 hours. On call told that baby known to Neonatology, on antibiotics, with history of tachypnea without hypoxia, with negative chest X-ray, had become hypoxic with grunting, and mild retractions, but decreased RR, I was advised that the baby probably had TTN and	MH-245-AH- MH-246-AH, MH-247-AH

DATE	FACILITY/ PROVIDER	MEDICAL EVENTS	BATES REF
		the management would be the same at their hospital and no transfer is needed at this time, if worse condition then call for transfer. I did express my concern of new hypoxia/retractions/ flaring; and my concern of the decrease in RR with new hypoxia. I was advised that it can occur with TTN and not necessarily a worsening on condition. The patient's condition worsened so transferred.	
09/16/YYYY - 09/17/YYYY	Provider/Hospital Name	<p>Other related records:</p> <p><i>Patient's Information</i> (Bates Ref: MH-8-AH- MH-10-AH)</p> <p><i>Assessment</i> (Bates Ref: MH-56-CLT- MH-57-CLT)</p> <p><i>Discharge Instructions</i> (Bates Ref: MH-52-CLT- MH-53-CLT)</p> <p><i>Intake output</i> (Bates Ref: MH-62-CLT)</p> <p><i>Medication Sheets</i> (Bates Ref: MH-143-AH- MH-144-AH, MH-280-AH- MH-282-AH)</p> <p><i>Orders</i> (Bates Ref: WPR-53-AH , MH-39-AH- MH-100-AH, MH-66-CLT- MH-127-CLT)</p> <p><i>Plan of care</i> (Bates Ref: MH-267-AH- MH-268-AH)</p>	
XXXX Hospital (09/17/YYYY – 10/03/YYYY)			
09/17/YYYY	Provider/Hospital Name	<p>NICU admission assessment: (<i>Illegible Notes</i>)</p> <p>Date of birth: 09/16/YYYY Time of birth: 1500 hours Birth weight: 3165 gm Admission weight: 3090 gm Length: 53 cm Head circumference: 36 cm Maternal fever: yes</p> <p>Glucose 25 ___ at 0630</p> <p>Other: Ampicillin 2000 hours – 09/16/YYYY Gentamicin 2040 hours – 09/16/YYYY</p> <p>Respiratory: Grunting, intercostal Tachypnea</p> <p>Neurological: Molding, caput Tremors Rhythmic movements of arms, ___ soft but full</p>	YH-219-AH- YH-220-AH

DATE	FACILITY/ PROVIDER	MEDICAL EVENTS	BATES REF
		<p>GI/GU: Scaphoid abdomen</p> <p>Admission note: 39 week 2 days baby male transferred to XXXX Hospital from XXXX Hospital due to increased work of breathing and increased O2 requirements. Infant presented with moaning/grunting, noises, arms and legs in bicycling motion (able to stop with soft pressure) however continuous motion, barrel chest and scaphoid abdomen (no bowel sounds heard in chest).</p>	
09/17/YYYY	Provider/Hospital Name	<p>@0428 hours: Assessment: <i>(Illegible Notes)</i></p> <p>Mode: ___ CPAP Rate vent: 68 FiO2 30 PEEP/CPAP: 8/8 Flow rate: 10 HR: 150 Oximeter: 94</p>	YH-221-AH- YH-222-AH
09/17/YYYY	Provider/Hospital Name	<p>@0500 hours: X-ray of chest:</p> <p>Indication: 39 weeks. Respiratory distress.</p> <p>Impression: No definite findings.</p>	YH-365-AH- YH-366-AH
09/17/YYYY	Provider/Hospital Name	<p>@0515 hours: Transfer Report: <i>(Illegible Notes)</i></p> <p>XXXX Hospital called for a term male with respiratory distress. On arrival, the baby was under an Oxyhood at 50% and appeared to be struggling in breath. He was grunting with severe retraction with arm and legs in ___ motion. We quickly changed to NCPAP of 8 and arterial blood gas revealed 7.20/26/40/14/-14. ___ was called with ___. Respiratory and ___ were comfortable transporting baby. RR went from 70s to 50s with CPAP and he was breathing easier. Baby had a very barrel chest appearance and I ___ the MD about his X-ray. She said a radiologist read and it was normal. Baby had an existing IV of D10 at 10 cc/hr. Glucose was stable, ___. Baby remained in constant motion with hip arms and legs. Some rhythmical motion of his arms were noted in the ambulance. He never opened his eyes. The transport to XXXX Hospital was uneventful and he remained, respiratory wise, stable.</p>	YH-344-AH- YH-345-AH, YH-340-AH- YH-343-AH
09/17/YYYY	Provider/Hospital Name	<p>@0813 hours: History and Physical:</p> <p>Chief complaint: This is a 39-2/7-week full-term male infant at day of life 1 who was admitted to XXXX Hospital NICU from XXXX Hospital for rule-out sepsis and respiratory distress.</p>	YH-22-AH- YH-26-AH

DATE	FACILITY/ PROVIDER	MEDICAL EVENTS	BATES REF
		<p>History of present illness:</p> <p>Maternal: The mother is an 18-year-old, blood type AB positive, G1 P0 female who is GBS-negative, RPR was nonreactive, rubella was immune, hepatitis B is negative, hepatitis C is negative. HIV is negative, gonorrhea and chlamydia are negative and the antibody screen was negative. A hemoglobin A1c done was 5.75. There is no significant past medical maternal history and current medications for the mother include prenatal vitamins. The mother denies alcohol, tobacco or drug use.</p> <p>Pregnancy: The mother was a late transfer to White Rose OE/GYN but did receive prenatal care. There is an EDC of September 21, 2015, based on a late ultrasound. There were no reported complications during this pregnancy. The mother presented to York XXXX Hospital on September 15, 2015, for an induction of labor due to nonreassuring fetal heart tones. During the antepartum period, there were rupture of membranes that were meconium-stained, and the membranes were ruptured for approximately 19 hours. During this time period, the mother did develop a fever and was given antibiotics.</p> <p>Labor and delivery: The infant was delivered via spontaneous vaginal delivery. The infant was depressed at birth and needed to be intubated for deep suction. It is unclear whether there was meconium beneath the cords or not. The infant also required some PPV and oxygen. Initial Apgar at one minute was 2, -2 for color, -2 for respiratory rate, -2 for reflex and -2 for tone, and 7 at five minutes, -1 for tone, -1 for color and -1 for reflex. A cord gas was obtained at the time of delivery which showed a pH of 7.19, pCO₂ of 56.2, HCO₃ of 21.9 and base deficit of -6.</p> <p>Neonatal course: The infant remained York XXXX Hospital and was started on Ampicillin and Gentamicin due to the prolonged rupture of membranes, maternal fever and the presentation. The infant had blood cultures drawn prior to starting the antibiotics. The infant was tachypneic shortly after birth and remained tachypneic throughout the evening and around 2:00 a.m. on September 17, 2015, had a significant increase in work of breathing and oxygen requirement. An initial X-ray at York XXXX Hospital showed adequate expansion and fairly clear lung fields with some slight fluid. At around 2:00 a.m., it was decided to transport the infant to XXXX Hospital for increasing oxygen needs and increasing work of breathing. Our transport team went to York Memorial to assess the infant. Upon arrival, the infant did have significant retraction and work of breathing. The infant was placed on 8 cm of CPAP via RAM. The infant was made nothing by mouth and was given IV fluids of D10W at 10 mL/h for the transport. A blood gas was obtained prior to leaving York Memorial which</p>	

DATE	FACILITY/ PROVIDER	MEDICAL EVENTS	BATES REF
		<p>showed a pH of 7.2, pO₂ of 36, bicarbonate 14 and base deficit of -14.</p> <p>Upon arrival to XXXX Hospital Neonatal ICU, the infant was placed under the radiant warmer and continued on CPAP of 8 cm at about 25%-30% FiO₂. The infant was tachypneic. A repeat blood gas on arrival showed a pH of 7.25, pCO₂ of 35, pO₂ of 33 and HCO 315 and base deficit of - 12. This was a heel stick. The infant was given a normal saline bolus of 40 mL over 30 minutes. The infant remained on the D10W and the rate was decreased to 8 ml/h. Blood sugar upon arrival was 25, and the infant was also given a bolus of D10W 6 ml one time. A CBC, I/T ratio was obtained at York XXXX Hospital which showed white blood cells of 20.5, hemoglobin 16.3, hematocrit 47 and platelets of 199. The CBC was from September 16, 2015, at approximately 5:00 p.m. A repeat CBC upon admission to XXXX Hospital NICU showed white blood cells of 12.2, hemoglobin was 15.6, hematocrit 44.1, platelets 154, segmented neutrophils 84, lymphocytes 9, monocytes 6, eosinophils 0, basophils 1 and I/T ratio 0. A CRP was 5.56. A CMP was collected upon arrival which showed a BUN 14, creatinine 1.15, sodium 137, potassium 5.5, chloride 107 and bicarbonate 14. Calcium was 8.7. A report are also came through shortly after the infant arrived to XXXX Hospital showing that the blood culture from York XXXX Hospital that was drawn in the evening was positive for gram-negative rods. Approximately 2 hours after the infant arrived to our NICU, his respiratory status was worsening, and he was becoming very tachypneic with very shallow breathing, so it was elected to intubate the infant. The infant was intubated with a 3.5 ET tube and placed on an SIMV rate of 30, tidal volume of 12, PEEP of 6 and pressure support of 6 with an inspiratory time of 0.4. Additionally, the infant had continuous movement, a bicycling motion with some posturing, so the infant was placed on a bedside aEEG monitoring, and Neurology is consulted. A chest X-ray was done which showed haziness in both the right and left upper lobes.</p> <p>Physical examination: General: This is a 30-2/7 week full-term male infant at day of life 1 who is now on mechanical ventilation and having significant respiratory distress under radiant warmer.</p> <p>Vital signs: Admission temperature was 36.1, axillary heart rate 169, respiratory rate 70 and blood pressure 70/44 with a mean of 59. Weight was 3165 grams, which is in the 25th percentile, head circumference 36 cm, which is in the 81st percentile, and length was 53 cm, which is in the 87th percentile. This is consistent with AGA.</p> <p>Skin: Pale, warm and dry. There are no rashes or lesions observed. HEENT: The infant has a significant caput succedaneum and the anterior fontanelle feels slightly full. The ears are symmetrical. The pupils appear unequal with right pupil being slightly more dilated than the left. There was a positive red reflex noted. They are also sluggish</p>	

DATE	FACILITY/ PROVIDER	MEDICAL EVENTS	BATES REF
		<p>to react to light. The nares are grossly patent. Mucous membranes were moist and pink. There was no cleft lip or palate observed.</p> <p>Neck: Supple with no masses.</p> <p>Lungs: There was fair air exchange. The infant is having very shallow rapid breathing with moderate suprasternal retractions.</p> <p>Heart: Normal sinus rhythm. There was no murmur auscultated. Infant did have +2 pulses brachially and femorally. The capillary refill was approximately 4 seconds.</p> <p>Gastrointestinal: Soft and nondistended. There were hypoactive bowel sounds. The liver is felt possibly slightly enlarged. Otherwise, there were no masses and the anus appeared grossly patent.</p> <p>Genitourinary: There are normal male testes.</p> <p>Extremities: There are no deformities of the hands, feet or spine. Hips: No subluxation.</p> <p>Neurologic: The tone is increased. The infant is doing frequent bicycling and swimming motion with his arms. The infant does have periods of arching and posturing, and the gag reflex appeared diminished.</p> <p>Impression: This is a 39-2/7 -week appropriate for gestational age infant who is in severe respiratory distress with metabolic acidosis and sepsis. This infant also has abnormal neurologic findings and meningitis and seizures need to be ruled out.</p> <p>Plan:</p> <ol style="list-style-type: none"> 1. Cardiorespiratory: We will continue to ventilate the infant on SIMV at the current settings. We will obtain a blood gas in an hour and adjust the settings as needed. We will obtain a chest X-ray to confirm placement. We will continue to follow the infant clinically. Echocardiogram may be considered if clinical condition worsens. 2. Metabolic: We will keep the infant nothing by mouth for now. We will obtain umbilical line central access with UAC and UVC. We will initiate UAC fluids of half sodium acetate at 0.5 mL/h, and we will continue on D10W at 8 mL/h. We will repeat the BMP in the morning, and we will continue to monitor the blood sugars needed and initiate hypoglycemia pathway as needed. 3. Hematologic: We will obtain TC bilirubins every shift. 4. Infection: We will increase the Ampicillin dose to 100 mg/kg per dose for a total of 200 mg/kg/d. We will consider doing a lumbar puncture to rule out meningitis, and we will continue to follow the blood cultures for sensitivity. We will continue to monitor the infant clinically for further signs and symptoms of infection. 5. Neurologic: We will obtain a Neurology consult this morning. We will continue to monitor the infant on the aEEG and consider a dose of Phenobarbital if the clinical condition warrants. We will also consider further imaging of the head to rule out any type of hemorrhage in the brain. There will be further plans as the patient's condition progresses. 	

DATE	FACILITY/ PROVIDER	MEDICAL EVENTS	BATES REF
		<p>Attending attestation: Assessment: 1. Term AGA newborn male 2. Gram-negative sepsis 3. Perinatal depression which seems out of proportion to his cord blood gas and fetal monitoring. This may be due to sepsis however, his metabolic acidosis also raises the concern of an inborn error of metabolism.</p> <p>Plan: 1. Continued general medical support of ventilation and cardiovascular needs. 2. We will perform a lumbar puncture (done). 3. Ongoing blood gas monitoring 4. Laboratory studies for cardiac enzymes, cerebral spinal fluid lactate and pyruvate, urine for organic acids and serum for amino acids. 5. Cranial ultrasound 6. Pediatric neurology consultation</p>	
09/17/YYYY	Provider/Hospital Name	<p>@0920 hours: Nursing notes: ETT pulled back to 9 at gum per chest X-ray/doctor</p>	YH-225-AH- YH-226-AH
09/17/YYYY	Provider/Hospital Name	<p>@0920 hours: X-ray of chest and abdomen: Indication: Central line placement</p> <p>Impression: 1. Endotracheal tube in distal trachea. 2. Possible mild right upper lobe collapse/atelectasis. 3. UVC catheter in good position at T8 level. 4. Normal bowel gas pattern.</p>	YH-364-AH- YH-365-AH
09/17/YYYY	Provider/Hospital Name	<p>@1135 hours: Neurology Consultation Report: Reason for consultation: The patient with possible seizures. History is provided by the Neonatal Intensive Care Unit Service and review of the admission note.</p> <p>History of present illness: The patient is a 39 week 2-day-old male, born on September 16th around 2:00 p.m. in the afternoon. Mother had presented on September 15th for induction due to nonreassuring fetal heart tones. There was prolonged rupture of membranes for 19 hours and there was meconium staining. During the labor, mother developed fever and was treated with antibiotics. Prenatal labs consist of GBS negative, RPR nonreactive, rubella immune, hepatitis B negative, hepatitis C negative, HIV negative, gonorrhea and chlamydia negative. Hemoglobin A1C was 5.75. There was reportedly no alcohol, tobacco or drug exposure.</p>	YP-17-REF- YP-19-REF

DATE	FACILITY/ PROVIDER	MEDICAL EVENTS	BATES REF
		<p>Medications include prenatal vitamins. There was prenatal care.</p> <p>The patient was delivered vaginally and was noted to have depression at birth and needed to be intubated for suctioning. He required positive pressure ventilation with some oxygen. Apgar scores were 2 and 7. Cord gas showed pH of 7.19, pCO₂ 56.2, bicarbonate 21.9 and base deficit of -6. It is unclear whether or not there was the presence of meconium beneath the vocal cords. Due to the prolonged rupture of membranes and maternal fever, Ampicillin and Gentamicin were started and blood cultures were also drawn prior to starting antibiotics. The patient developed tachypnea, which was progressively worsening around 2:00 a.m. on September 17th, and was requiring oxygen and was then transferred to XXXX Hospital from XXXX Hospital. X-ray initially was normal. On arrival here, the patient was retracting with respiratory distress and started on CPAP. His blood gas prior to leaving XXXX Hospital was pH of 7.2, pO₂ 36, bicarbonate 14 and base deficit -14. He was found to be hypoglycemic at 25 and was required boluses of D10. Initial CBC from 5:00 p.m. on September 16th showed white blood cell count of 20.5, hemoglobin 16.3, hematocrit 47 and platelet count 199. CRP was 5.56. Basic metabolic panel upon arrival to XXXX Hospital showed sodium 137, potassium 5.5, chloride 107, BUN 14, creatinine 1.15, bicarbonate was 14, also and calcium was 8.7, blood culture was found to be positive for gram-negative rods.</p> <p>The patient has subsequently been intubated for shallow breathing and tachypnea and is on SMV mode. He has some bicycling movements and extension posturing so amplitude integrated EEG was placed. Subsequent X-ray shows some haziness of upper lobes bilaterally.</p> <p>The patient has been stabilized with line placement and interpretable portions of the amplitude integrated EEG, even though recording was started at 5:25. There are some technical difficulties and period of time where the tracing is actually not recording from 6:20 to about 7:20 this morning and interpretable EEG starting at 7:30 am. forward, this is very abnormal with symmetric suppression of activity of the bilateral hemispheres with some activity resembling seizures. He is not in status epilepticus, EEG is very abnormal.</p> <p>The patient's repeat white blood cell count this morning at 5:30 a.m. was 12.2, hemoglobin 15.6, hematocrit 44, platelet count 154, neutrophils 84%, lymphocytes 9% and 6% monocytes. Electrolytes are as documented above.</p> <p>Physical examination: Neurologic: The patient has just had all the lines placed and the draping are still in place. These were removed to allow for the examination. He has intermittent posturing of his upper extremities and lower extremities. There was 1 seizure where his eyes had some</p>	

DATE	FACILITY/ PROVIDER	MEDICAL EVENTS	BATES REF
		<p>mild blinking and deviation to the right with extension of his bilateral arms. Other times, the patient has chewing movements, which are not seizures per review with the amplitude integrated EEG.</p> <p>His anterior fontanelle is somewhat full and there was a caput succedaneum on the right side. There were no facial dysmorphic features.</p> <p>Extremities: Well perfused.</p> <p>Heart and lungs: Not examined, but by observation, the patient is tachypneic and is intubated.</p> <p>He opens his eyes spontaneously. Pupils are intermittently equal in size. Right pupil is slightly larger than the left. They are both reactive, though.</p> <p>The patient does have a sucking reflex on a gloved finger.</p> <p>Abdomen: Soft and nondistended.</p> <p>Extremities: His tone is increased in his arms and legs. His legs tend to be extended at the hips and it is difficult to flex them at the hips and the knees. This is somewhat persistent while the upper extremities are typically in extension. He does have a cortical thumb on the right and the left arm is boarded with the IV so it is difficult to assess for this presence of this on that side. He does have palmar grasp on the right.</p> <p>Impressions: Patient with respiratory distress, metabolic acidosis, sepsis with blood culture showing gram-negative rods. His examination is very abnormal with abnormal EEG showing suppression of activity and seizure activity but not status epilepticus.</p> <p>Plan: 1. The patient will be loaded with phenobarbital and started on maintenance Phenobarbital. Checking of electrolytes at the frequency at the discretion of the Neonatal Intensive Care Unit since he has had hypoglycemia. Recommend neuroimaging when possible; however, the patient does require lumbar puncture to determine if there is the presence of meningitis. I would also agree with starting Acyclovir as we do not know if the patient has HSV encephalitis or meningitis. 2. Recommend a full head, EEG when able. Hopefully today to determine if this is burst suppression that the patient is having. The plan was discussed with the primary service.</p>	
09/17/YYYY	Provider/Hospital Name	<p>@1240 hours: Procedure Report:</p> <p>Procedure: NICU central line insertion</p> <p>Insertion: UVC, PAL (right radial artery) Secured at 10.5 cm – UVC</p> <p>UA unsuccessful</p> <p>X-ray/adjustment: Good position on 1st film</p>	YH-200-AH

DATE	FACILITY/ PROVIDER	MEDICAL EVENTS	BATES REF
09/17/YYYY	Provider/Hospital Name	<p>@1319 hours: Ultrasound head:</p> <p>Indication: 1 day old. Seizures. 39+2 week gestation.</p> <p>Impression: Normal neonatal brain ultrasound.</p>	YH-370-AH- YH-371-AH
09/17/YYYY	Provider/Hospital Name	<p>@1350 hours: Progress Notes: (<i>Illegible Notes</i>)</p> <p>39 week 2 day ___ transferred to XXXX Hospital from XXXX Hospital at 0428 hours this morning due to respiratory distress with increased O2 requirement. Infant ___ to NICU with ___ bicycle motion of arms and legs (constant motion) – able to step bicycling with firm touch however continued motion ___. Infant also presented barrel chest, scaphoid abdomen (as bowel sounds ___ in chart). Transferred on CPAP at 8 cm and quickly converted to bubble CPAP at 8 cm with FiO2 25 -> 40% to keep sats more than or equal to 88%. PIV inserted at left hand to infuse D10W at 10 ml/hr -> 8 ml/hr. HR increased to 180s – NSS bolus 40 ml given ___ 30 min – no change in HR after bolus. A EEG line inserted and started. ___ 25 -> D10W and IV bolus given. Follow up ___ =65-71 (after IV start). Infant intubated at 0700 hours due to increased work of breathing with FiO2 increased to 45% -> SIMV 30, VT 12, PEEP 6, p/s 6, IT0.4, FiO2 39-45%. Infant continued with constant motion, given Fentanyl 6 mcg IV. UVC inserted ___. Dr. ___ to infuse D10 with ½ ___ at 8 ml/hr. D10W discontinued from heplock. Chest X-ray done x2 – lungs ___ infiltrate per Dr. ___. Pulled back on ETT by 1 cm. HR continued to increase 180-200 – admin NSS 65 ml over 30 mins with HR decreased to 160s. Dr. ___ approx. 0930 hours for neuro consult and she reviewed AEEG and ___ infant behavior with ___. ___ seizure activity noted. However, now infant legs are straight and stiff with some clonus of feet bilaterally. Phenobarbital ___ IV given at 1040 hours. Lumbar puncture done by ___ - new ___ given for Ampicillin and Gentamicin. Ampicillin 316.5 mg given at 0815 hours ___ due at 2030 hours today. Radial arterial line inserted at right wrist by Dr. ___ - ___ dampened waveform pattern; ___ of right hand was pale pink ___. Blood easily obtained via radial arterial line. ___ done x3. At 1330 hours – 7.40/19/60/12/-13. Follow up gas at 1440 hours. ___ SIMV decreased 15 (1210) and decreased to 10 (1340). Fluid NSS bolus (60 ml) given at 1220 hours over 30 mins. Currently HR 170S. Acyclovir given ___. Head ultrasound done at 1200 hours. MD + CRNP spoke with mom several times today; mom might be discharged today. Will keep in context with family. Currently infant given with minimal/movements of extremities; open eyes briefly.</p>	YH-179-AH- YH-180-AH
09/17/YYYY	Provider/Hospital Name	<p>@1653 hours: Neonatology Progress Notes:</p> <p>Physical examination:</p> <p>Objective: He was reweighed this morning and his weight is 3090 grams.</p> <p>Vital Signs: Show some mild tachycardia with heart rates up to 180,</p>	YH-153-AH

DATE	FACILITY/ PROVIDER	MEDICAL EVENTS	BATES REF
		<p>responsive to volume expansion with normal saline solution. Blood pressure most recently 78/44 with a mean of 59. He continues on mechanical ventilator support, intubated early this morning because of hypercarbia and his most recent blood gas showed a pH of 7.40, 18, 49, 11, -13 and 86% saturation. His vent support is currently an SIMV of 10 with pressure support of 6 cm, tidal volume 12 ml, PEEP 6 and inspiratory time is 0.4 seconds. His saturations are 92%. He is in about 40% oxygen on average.</p> <p>Assessment: I am very concerned that his respiratory status, namely, his low pCO₂ and normal pH, are due to central neurogenic hyperventilation and that this is secondary to either postasphyxia or accumulated acidosis, possibly from an inborn error. We have sent off lab studies looking for lactate and pyruvate and another set of electrolytes to measure anion gap. We also have sent urine for organic acids.</p> <p>Plan: Every 2-hour blood gases, careful monitoring and consideration of possible metabolic etiology.</p> <p>Cardiovascular: His blood pressure is normal, but he does have a history of perinatal depression and nm has a positive blood culture and has had some signs of hypovolemia with improvement with volume expansion, so we are going to start some Dopamine at a low dose of 5 micrograms per kilogram per minute and see how this affects his blood pressure, heart rate and urine output. His hemoglobin and hematocrit this morning were 15.6 and 44.1 and his platelet count is normal. I/T is 0. His blood culture is positive for gram-negative rod at XXXX Hospital, although his CBC is not remarkable. His CRP is over 5. We are treating him with a meningitic doses of Ampicillin plus Gentamicin and I have obtained spinal fluid which shows no evidence of meningitis. The Gram stain from CSF is negative for organisms or polys and there are many red blood cells. Cranial ultrasound is normal. His neurologic examination is significant for asymmetric pupils and a more sluggish pupillary reflex on the right. He is being monitored with an EEG which has demonstrated seizure activity, so he has been loaded with Phenobarbital 25 mg/kg and this has brought about stabilization in his clinical appearance with less random upper extremity movement. His tone remains abnormal; however.</p> <p>Assessment: In summary, this is a term newborn male who has a positive blood culture for gram-negative rods and a neurologic circumstance and examination somewhat out of proportion to his initial clinical scenario raising the question about an inborn error of metabolism. He does, however, have a positive blood culture, so this could all be related to perfusion issues secondary to gram-negative endotoxemia.</p>	

DATE	FACILITY/ PROVIDER	MEDICAL EVENTS	BATES REF
		Plan: Check an ammonia, CMP cardiac labs change him to D11 and start 5 micrograms/kg/minute of Dopamine and we will repeat an AP chest X-ray. Further plans as clinical course progresses.	
09/17/YYYY	Provider/Hospital Name	<p>@1940 hours: Progress notes: (Illegible Notes)</p> <p>Assumed care at 1500 hours. Vent settings remain unchanged. SIMV 10, TV 12, PEEP 6, PS 6, ____, FiO2 40%, weaned to 30%. Breath sounds coarse, ETT exchanged for large amounts of thick clear secretions with breath sounds clearing. ____ for a small amount of clear secretions. RR 86, low 100s, ABG done every 2 hours and ____ given. Bicarb given in ____ at 1815 hours. HR at rest approx. 150-160s. However, there are ____ when HR increased to 200 BPM with MBP increased to 65-67 (from ____). ____ no rhythmic movements observed. No murmur, pale/pink, ____ started in left ____ at 5 mcg/kg/min. Right ____ now intermittent dampening. ____ Multiple left ____ started ____ start of shift. ____ given to Dr. ____, urine not yet collected, but ____ bag in place. Urine output 1.5 kg/hr ____. Pink in color, ____ NPO. No ____ seizures observed. EEG continued. Temp stable. Received Phenobarb today. ____ Levophed and asked about ____.</p>	YH-178-AH
09/17/YYYY	Provider/Hospital Name	<p>Lab report:</p> <p>Creatinine 0.90, sodium 136, potassium 4.7 (L), CO2 12 (L), anion gap 18 (H)</p>	YH-377-AH- YH-378-AH
09/17/YYYY	Provider/Hospital Name	<p>Lab report:</p> <p>Glucose 82, albumin 3.2 (L), alkaline phosphatase 85 (L), AST 123 (H), ALT 30, total bilirubin 6.5 (H), direct bilirubin 0.7 (H), CK 9178 (H), CKMB 143.9 (H), troponin I 0.06 (H), ammonia 113 (H)</p>	YH-376-AH
09/17/YYYY	Provider/Hospital Name	<p>Blood gases:</p> <p>pH 7.46 (H), pCO2 19 (L), pO2 46 (L), HCO3 14 (L), base excess -10 (L), O2 sat 86 (L)</p>	YH-395-AH
09/17/YYYY	Provider/Hospital Name	<p>Urine analysis:</p> <p>Lactic 3526 (H), Glycolic 156 (H), 3-Hydroxyisobutyric 214 (H), 3-Hydrobutyric 832 (H), 2-Hydroisovaleic 58 (H), 2-Ethyl-3-hydropropionic 66 (H), 5-Hydroxyhexanoic 76 (H), Pyruvic 332 (H), 2-Oxoisovaleic 40 (H), acetoacetic 34 (H), 2-Oxo-3-Methylvaleric 24 (H), Homovanillic 26 (H), Isocitric 30 (L), urine crea organic acid 4.05 (H)</p>	YH-396-AH- YH-400-AH
09/17/YYYY	Provider/Hospital Name	<p>Lab report:</p> <p>CRP 5.52 (H)</p>	YH-388-AH
09/17/YYYY	Provider/Hospital Name	<p>Lab report:</p> <p>CSF panel: Appearance yellow, WBC 13, RBC 325, CSF volume 4.0, glucose 38, protein 142, lactic acid 8.0</p>	YH-375-AH

DATE	FACILITY/ PROVIDER	MEDICAL EVENTS	BATES REF
09/17/YYYY	Provider/Hospital Name	<p>Lab report:</p> <p>Aminoacid: Aspartic acid 1 (L), Glutamic acid 14 (L), Serine 60 (L), Threonine 46 (L), Beta-amino butyric acid 40 (H), proline 406 (H), ethanolamine 127 (H), Cystathione 1 (H), Phenylalanine 88 (H), Tryptophan 8 (L), Ornithine 6 (L)</p>	YH-382-AH- YH-384-AH
09/18/YYYY	Provider/Hospital Name	<p>@0715 hours: Critical Values Report:</p> <p>Lactate 4.4</p>	YH-177-AH
09/18/YYYY	Provider/Hospital Name	<p>@1026 hours: CT of head without contrast:</p> <p>Indication: Newborn at 39 weeks, abnormal tone and pinpoint pupils.</p> <p>Impression: There is diffuse hypodensity of both cerebral hemispheres and posterior fossa strongly suggests diffuse cerebral edema and global anoxic or hypoxic encephalopathy. No intracerebral or subdural hemorrhage.</p> <p>Report faxed to NICU by Karen Ritter on 9/18/YYYY at 1100 hours and confirmed by Brittany Logue, NA, who gave to Dr. John Rouhani.</p>	YH-362-AH- YH-363-AH
09/18/YYYY	Provider/Hospital Name	<p>@1139 hours: Neonatology Progress Notes:</p> <p>Day of life 2</p> <p>Physical examination: Weight is 3090 grams, a decrease of 26 grams.</p> <p>Vital Signs: Temperature 37, 176 heart rate, 73 respiratory rate and blood pressure 62/49 with a mean of 55.</p> <p>Heart and lungs: Spontaneously breathing and has fair exchange bilaterally. He has normal first and second heart sounds. All the pulses are felt normally.</p> <p>Central nervous system: The baby does not have as mild much spontaneous movements and both the eyes show bilateral VII nerve palsy with no lateral deviation of the eyes with the dolls eye maneuver. No evidence of gag reflex. No evidence of corneal reflexes noted. The baby's tone in all the 4 limbs is increased.</p> <p>Abdomen: Round, but soft.</p> <p>Skin: Mild jaundice.</p> <p>Cardiorespiratory: Objective: The baby is currently on CPAP with pressure support. He is on a CPAP with a PEEP of 6 and a pressure support of 6, FiO2 between 30%-34%. The blood gas this morning was 7.49 pH, 25 pCO2, 81 pO2 with a -4 base deficit. He is also on Dopamine at 3 micrograms/kg/minute. We have done the lactate level today and it is</p>	YH-151-AH- YH-153-AH

DATE	FACILITY/ PROVIDER	MEDICAL EVENTS	BATES REF
		<p>4.4 and the serum sodium is 128, 4 potassium, 0.55 creatinine. 97 chloride, 18 bicarb, 10 BUN and 104 glucose.</p> <p>Assessment: Baby has central hyperventilation with respiratory alkalosis with minimal metabolic acidosis. The baby did have a significant metabolic acidosis with a lactate of 8 in the cerebrospinal fluid, a lactate of 4.4 in the blood and had received around 9 mEq/kg of sodium bicarbonate since last night and also around 60 ml/kg of normal saline boluses. Since morning, the metabolic acidosis seems to have improved significantly with more of a respiratory alkalosis.</p> <p>Plan: At this point, we could continue the Dopamine at 3 micrograms/kg/minute. We will closely monitor the baby's cardiorespiratory status.</p> <p>Central nervous system: Objective: As the baby does not have any spontaneous activity, the pupils are small and pinpoint and no brainstem reflexes are noted Dr. Todd Barron saw the baby and felt that the baby has a flat amplitude integrated EEG and he is on a regular EEG to see if the baby has any cerebral electrical activity. A CT scan was suggested to see if the baby has any significant brain damage. The CT scan showed diffuse hypodensity of both cerebral hemispheres and the posterior fossa strongly suggestive for diffuse cerebral edema and global anoxic hypoxic encephalopathy. Dr. Todd Barron advised that we do a head ultrasound with Doppler flow, as the baby cannot go down for an MRI at this point, to see if there is any pain cerebral sinus thrombosis which may explain why there such diffuse cerebral damage. We will discontinue the Phenobarbital for now. Serum ammonia is done and ammonia is 78, which is not suggestive of any inborn error of metabolism at this point.</p> <p>Infectious disease: Objective: The baby is currently on Ampicillin and Gentamicin. Cefotaxime has been added as baby is growing E. coli from the blood cultures drawn from XXXX Hospital. The CSF culture done yesterday does not show any evidence of any infection including the Gram stain.</p> <p>Hematologic: Objective: White count 18.5, hematocrit 36.6, I/T 0.09 and 123,000 platelets. Direct bilirubin 7.6. Plan: Continue to monitor the CBCs and we will get one around 6:00 p.m. to see if there is any further drop in the platelets and the baby requires any transfusion.</p> <p>Metabolic: Objective: The baby is currently nothing by mouth, has a UVC with D11 Dextrose with a quarter sodium acetate going around 8 ml per hour. Has a peripheral IV with Dopamine at 3 micrograms/kg/minute and has a radial arterial line with half sodium acetate at 0.5 ml per hour. Had a urine of 3.7 ml/kg/h in the last 5 hours and has had 1 stool.</p>	

DATE	FACILITY/ PROVIDER	MEDICAL EVENTS	BATES REF
		<p>Plan: As the baby did have significant neurological deficits as well as the metabolic acidosis, the plan is to keep the baby nothing by mouth for now and we will give D11 Dextrose with half sodium acetate with calcium and potassium to be done at the same rate. We will closely monitor the baby's electrolytes and BMP at around 4.00 p.m.</p>	
09/18/YYYY	Provider/Hospital Name	<p>@1415 hours: EEG report:</p> <p>History: A 2-day-old with neonatal encephalopathy. A CT scan demonstrating diffuse bilateral ischemic changes.</p> <p>Medications:</p> <ol style="list-style-type: none"> 1. Phenobarbital 2. Dopamine 3. Cefotaxime 4. Gentamicin 5. Acyclovir 6. Ampicillin <p>Conditions: Portable tracing obtained at the patient's bedside in the Neonatal Intensive Care Unit.</p> <p>Interpretation: As the tracing opens, the baby is unresponsive. The eyes are closed. The background is obscured in part by EMG artifact. There is complete absence of cortical rhythms. The background is completely suppressed. At times, prominent EKG/pulse artifact are identified in the temporal leads, later, the patient is administered Vecuronium. There is complete disappearance of the EMG artifact and persistence of the EKG artifact. Sensitivities are increased to 1 microvolt with appearance only of EKG artifact noted. There is once again complete absence of cortical rhythms. The patient is stimulated with no change in the electrographic tracing. There were no asymmetries or potentially epileptiform abnormalities. EKG demonstrated a regular rhythm.</p> <p>Impression: This is an isoelectric tracing.</p>	YH-21-CLT- YH-22-CLT
09/18/YYYY	Provider/Hospital Name	<p>Lab report:</p> <p>Creatinine 0.48 (L), sodium 121 (L), potassium 4.7, CO2 17 (L)</p>	YH-377-AH- YH-378-AH
09/18/YYYY	Provider/Hospital Name	<p>Lab report:</p> <p>RBC 3.94 (L), Hemoglobin 13.8 (L), hematocrit 36.3 (L), platelet 108 (L)</p>	YH-386-AH- YH-387-AH
09/18/YYYY	Provider/Hospital Name	<p>Lab report:</p> <p>Glucose 94, albumin 2.9 (L), alkaline phosphatase 73 (L), AST 120 (H), ALT 33, total bilirubin 7.0 (H), direct bilirubin 0.6 (H), lactic acid 4.4 (H), ammonia 78 (H)</p>	YH-376-AH

DATE	FACILITY/ PROVIDER	MEDICAL EVENTS	BATES REF
09/18/YYYY	Provider/Hospital Name	Blood gases: pH 7.42, pCO2 27 (L), pO2 43 (L), HCO3 17 (L), base excess -7 (L), O2 sat 80 (L)	YH-394-AH
09/18/YYYY	Provider/Hospital Name	Lab report: CSF panel: Appearance yellow, WBC 21, RBC129, CSF volume 5.0	YH-375-AH
09/18/YYYY	Provider/Hospital Name	Lab report: CSF Aminoacid analysis: Hydroxyproline <1 (L), Asparagine 37 (H), Glutamine 1703 (H), histidine 46 (H), Alpha-amino butyric acid 11 (H), Valine 32 (H), Methionine 24 (H), Leucine 26 (H), Phenylalanine 50 (H), Tryptophan 12 (H), Pyruvate 2.01 (H)	YH-389-AH- YH-391-AH
09/18/YYYY	Provider/Hospital Name	Lab report: CSF panel: CSF glucose 87, protein 99, lactic acid 3.0	YH-375-AH
09/19/YYYY	Provider/Hospital Name	@0957 hours: Neonatology Progress Notes: Day of life: 3. Physical examination: Weight is 3650 grams, which is an increase of 560 grams. Vital Signs: Temperature 36.5, 148 heart rate, respiratory 37-75, blood pressure 56/41 with a mean of 49. Heart and lungs: Fair exchange bilaterally, breathing spontaneously. Has normal first and second heart sounds. All the pulses are felt normally. Central nervous system: The baby is beginning to show some spontaneous movements of the arms mostly and with bicycling movements noted. The tone is still increased in all the limbs, especially in the lower limbs and patellar reflex was elicited on the left knee, but not on the right side. The baby does move the eyes laterally on doll's maneuver. The pupils are reacting. The right is slightly bigger than the left. Abdomen: Round, but soft. Normal bowel sounds heard. Cardiorespiratory: Objective: The baby is on CPAP with pressure support of 6 and a PEEP of 6 and FiO2 around 26%. Blood gas this morning was 7.36, pH 7.38, pCO2 48, PaO2 with a -4 base deficit. Assessment: The baby has been breathing spontaneously and the blood gases are becoming more normal today. Plan: Follow every 6-hourly blood gases and will follow with an I-STAT 6+ around 10:00 and repeat the G7 at around 6:00 p.m.	YH-150-AH- YH-151-AH

DATE	FACILITY/ PROVIDER	MEDICAL EVENTS	BATES REF
		<p>Infectious disease: Objective: The baby has grown E. coli from the blood cultures drawn from XXXX Hospital and repeat blood cultures were done yesterday. Blood cultures so far have been negative. We also did a CSF analysis yesterday, a repeat one, which showed 21 white cells, 129 RBCs, the glucose is 87 and protein is 99 which is completely normal and acceptable, showing no evidence of any bacterial meningitis in the baby. Herpes simplex virus PCR from the initial CSF was also negative. The lactate level in the CSF is 3, which is less than 6, which is normal in a newborn infant. Plan: Discontinue the Ampicillin as E. coli is resistant to Ampicillin. We will continue Gentamicin and Cefotaxime for now and if the second blood culture is also negative, we would discontinue one of the antibiotics.</p> <p>Hematologic: Objective: White count is 13.1, hemoglobin is 14.4, hematocrit is 37.4, I/T is 0.01, 106,000 platelets. The baby has mild thrombocytopenia. Plan: Follow up with a CBC in the morning. The lactate level was done which is 3.2 which has decreased from 4.4 yesterday. Ammonia level was repeated yesterday and had decreased from 113 to 78 yesterday.</p> <p>Central nervous system: Objective: The baby did have a CT scan done yesterday which showed a diffuse cerebral edema with no white and gray matter differentiation and ventricles are very small and slit-like. Dr. Todd Barron had spoken to the parents and explained to them that the baby has a very poor prognosis with a possibility of not able to eat by mouth or talk or see and the parents do understand the grave prognosis for the baby, but at the same time we do not know what exactly is the reason in this baby as meningitis has been ruled out, but the CNS examination today is more or less same as yesterday. Plan: We will closely follow.</p> <p>Metabolic: Objective: He is currently nothing by mouth, has a UVC with D11 Dextrose with 1/2 sodium acetate with potassium and calcium at 8 ml/h and has a radial arterial line at 1/4 sodium acetate at 0.5 ml/h with a 0.5 unit of Heparin per ml. He has received 136 ml/kg/d, 23 kcal/kg/d, 2.3 ml/kg/h of urine output and 3 stools. The baby has received 3 infusions of 3s saline for significant hyponatremia. Despite the 3% saline the sodium early this morning was 121 and he has just finished the third infusion of 3% saline. Plan: We will follow up with an I-STAT 6+ around 10:00 and consider giving another saline infusion if it is still low. The plan is to start the baby on Hyperal of D12 with 8 mEq/kg of sodium to run at</p>	

DATE	FACILITY/ PROVIDER	MEDICAL EVENTS	BATES REF
		9.2 ml/h and Intralipids at 0.65 and will give total fluids of 80 ml/kg/d at this point. We will follow up with a BMP tomorrow morning and a G7 around 6:00 to see if the baby has normal sodium.	
09/19/YYYY	Provider/Hospital Name	<p>@1030 hours: X-ray of chest:</p> <p>Indication: Respiratory distress</p> <p>Impression: Support lines and tubes in good position Improved lung volumes. No edema, pneumonia, atelectasis or pneumothorax.</p>	YH-363-AH- YH-364-AH
09/19/YYYY	Provider/Hospital Name	<p>@1224 hours: Pediatric Neurology Progress Notes:</p> <p>Subjective: Intermittent bicycling type of movements of arms. Breathing over minimal pressure support. Has had hyponatremia and required four, 3% saline boluses since 9/18.</p> <p>Objective: Patient examined at approximately 11 AM.</p> <p>Physical examination: General: Spontaneous, non-purposeful movements of arms. Has IV board on both arms. Anterior fontanelle was full but soft. No splaying of sutures. Neurologic: Cranial nerves; Pupils very sluggishly, minimally reactive, right pupil slightly larger than left. Gaze is conjugate at midline without sixth nerve palsies. Only once had a partial left corneal reflex. Right corneal absent. Gag reflex present. Symmetric and intact facial grimace that was consistent. Patient yawned a few times. Motor: Movements as documented above. Tone fluctuates in his lower extremities - they can be fully flexed at knees and hips and other times he is rigid. Arms are extended but also boarded with IV placement. Deep tendon reflexes: Absent Sensory: No withdrawal with stimulation.</p> <p>Labs: 09/19/YYYY: WBC 13.1, hemoglobin 14.4 (L), hematocrit 37.4 (L), platelet 108 (L), sodium 121 (L), potassium 5.2, CO2 16 (L), chloride 95 (L), creatinine 0.38 (L), BUN 7</p> <p>Medications: Cefotaxime 155 mg 0.78 ml, every 12 hours Gentamicin 12.5 mg 1.26 ml every 24 hours Dextrose 10% 250 ml 8 ml/hr Fat emulsion 20% 46 ml 0.85 ml/hr Sodium acetate 18.25 mEq + Heparin preservative free 250 units + water for inj 487.87 ml</p>	YH-133-AH- YH-135-AH

DATE	FACILITY/ PROVIDER	MEDICAL EVENTS	BATES REF
		TPN – neonatal 500 ml Vitamin A-Vitamin D oint topical Zinc oxide topical 13% cream topical Assessment: Patient is DOL 4 born at 39 weeks, with severe encephalopathy and brain edema of multifactorial etiology as outlined by Dr. Barron’s note on 09/18. Resolving respiratory distress and acidosis, persistent hyponatremia likely from SIADH and cerebral salt wasting. He is showing some recovery of brainstem reflexes, but no evidence of higher cerebral functioning. The brainstem function and his neurologic examination are markedly abnormal, consistent with the isoelectric, unreactive brain activity on EEG. Movements he is having are not seizures. Plan: Continue supportive care May consider repeating EEG on 9/21 to assess for any changes if his examination improves.	
09/19/YYYY	Provider/Hospital Name	Lab report: Creatinine 0.36 (L), sodium 121 (L), potassium 5.2 (H), CO2 15 (L)	YH-377-AH- YH-378-AH
09/19/YYYY	Provider/Hospital Name	Lab report: Glucose 100, lactic acid 3.2	YH-376-AH
09/19/YYYY	Provider/Hospital Name	Lab report: RBC 4.09 (L), Hemoglobin 14.4 (L), hematocrit 37.4 (L), platelet 91 (L)	YH-386-AH- YH-387-AH
09/19/YYYY	Provider/Hospital Name	Blood gases: pH 7.43, pCO2 39, pO2 69 (L), HCO3 26, base excess 2, O2 sat 94	YH-393-AH
09/19/YYYY	Provider/Hospital Name	Herpes Simplex Virus PCR: Source: CSF lumbar puncture Collected date: 09/17/YYYY Final report: Herpes Simplex virus not detected	YH-400-AH
09/20/YYYY	Provider/Hospital Name	@1015 hours: Neonatology Progress Notes: Physical examination: Weight is 3550 grams, increase of 100 grams. Vital Signs: Temperature 36.7, 135 heart rate, respiratory is 41, blood pressure 59/30 with a mean of 48. Heart and lungs: Fair exchange bilaterally. Has normal first and second heart sounds. All the pulses are felt normally and equally. Abdomen: Soft, normal bowel sounds are heard. Central nervous system: The baby has very decreased spontaneous activity. The tone has decreased to almost hypotonic. No doll's eye	YH-148-AH- YH-149-AH

DATE	FACILITY/ PROVIDER	MEDICAL EVENTS	BATES REF
		<p>reflex is noted. There is occasional cough noted. No evidence of any corneal reflex, but both the knee jerk reflexes are present.</p> <p>Cardiorespiratory: Objective: The baby is placed on SIMV since last evening at a rate of 20, tidal volume of 13, PEEP of 6, pressure support of 7, I-time 0.4 in room air. The blood gas was 7.44 pH, 45 pCO₂, 68, pO₂. He is also on Dopamine at 5 micrograms per kilogram per minute. Assessment: The baby's spontaneous breathing has decreased significantly and hence the baby is requiring more support from the ventilator. Plan: To take all the acetate from all the fluids so as to help to reduce the metabolic alkalosis pattern which may help with the spontaneous breathing.</p> <p>Central nervous system: Objective: The baby currently has almost the same examination as yesterday, but has gotten more of a hypotonia and decreased breathing. Plan: Get an EEG as well as a Phenobarbital level tomorrow. The baby's current CNS condition is very critical and Dr. Jena Khera has also examined the baby yesterday and agreed with the same. The lactate level today is 2.7, which has decreased from 3.2 yesterday despite being on hyperalimentation.</p> <p>Hematologic: Objective: White count is 10.1, hematocrit is 33.3, I/T is 0, 73,000 platelets. The baby is developing significant thrombocytopenia at this point. We will not transfuse the platelets, but we will follow up with a CBC in the morning.</p> <p>Metabolic: Objective: He is currently nothing by mouth. He has a UVC with D12 hyperal at 9.2, intralipids at 0.65, Dopamine at 0.59 and a radial arterial line with half sodium acetate at 0.5 ml per hour with half unit of Heparin per ml. He has received 67 ml/kg, 31 kcal/kg/d, 2.6 ml/kg/h of urine output and 2 stools. The urine output since midnight is around 8.3 ml/kg/h. Sodium is 146, 4 potassium, 108 chloride, 29 bicarbonate. 6 BUN, 0.31 creatinine. 8.6 calcium, 87 glucose. Assessment: The baby had severe hyponatremia, which was corrected with sodium and also with a high amount of sodium in the hyperal. As the sodium is now 146 the plan is to decrease the total sodium in the IV fluids to around 3 mEq/kg. We will change the acetate in the radial arterial line to 1/4 sodium chloride in the radial arterial line. We will keep the total fluids at 100 ml/kg with D12 at 10.5 and intralipids at 1.29 ml per hour.</p>	
09/20/YYYY	Provider/Hospital Name	<p>Lab report: BUN 6 (L), creatinine 0.31 (L), sodium 146 (H), chloride 108 (H), CO₂ 29</p>	YH-377-AH- YH-378-AH

DATE	FACILITY/ PROVIDER	MEDICAL EVENTS	BATES REF
09/20/YYYY	Provider/Hospital Name	Lab report: Glucose 87, lactic acid 2.7	YH-376-AH
09/20/YYYY	Provider/Hospital Name	Lab report: RBC 3.58 (L), Hemoglobin 12.5 (L), hematocrit 33.3 (L), platelet 73 (L)	YH-386-AH- YH-387-AH
09/20/YYYY	Provider/Hospital Name	Blood gases: pH 7.46 (H), pCO2 47, pO2 77, HCO3 34 (H), base excess 10 (H), O2 sat 96	YH-392-AH
09/20/YYYY	Provider/Hospital Name	CSF culture and gram stain: Source: CSF lumbar puncture Collected date: 09/17/YYYY Gram stain: Few polymorphonuclear leukocytes Many erythrocytes No bacteria Final report: No growth	YH-400-AH
09/21/YYYY	Provider/Hospital Name	@0928 hours: Pediatric Neurology Progress Notes: Subjective: Last Fentanyl at 12:08 PM on 9/18. Last Phenobarbital at 11:17 AM on 9/18 - level this morning at 6 AM was 21.5. Has been on Dopamine 9/19 for hypotension and was started on SIMV then as limited spontaneous respirations. Hyponatremia has resolved - last sodium acetate on 9/19. Objective: Patient examined at approximately 9 AM. Exam fluctuates while it is being performed. General: Rare spontaneous non-purposeful movement of arm. Has IV board on right arm. Anterior fontanelle was full but soft. No splaying of sutures. Does not cry or grimace when head is vigorously rubbed to remove EEG glue. Heart: Regular rate and rhythm. Lungs: Clear bilaterally, ET tube in place, on SIMV. Abdomen: Soft, nondistended, no palpable masses or Hepatosplenomegaly. Extremities: Well perfused. No edema. Neurologic- Cranial nerves: Left pupil is fixed and unreactive at 2 mm. Right pupil is slightly larger and very sluggishly reactive. Right pupil remains slighter larger than left. Erratic, jerky type of eye movements. Corneal reflexes elicited on either side – several times it was not present though. Gag reflex present. Symmetric and intact facial grimace that was consistent. Patient yawned many times.	YH-131-AH- YH-133-AH

DATE	FACILITY/ PROVIDER	MEDICAL EVENTS	BATES REF
		<p>Chewing type of movements on ET tube.</p> <p>Motor: Movements are mainly of arms - mild flailing type with arms extended. Tone again fluctuates in his lower extremities - they can be fully flexed at knees and hips, limited spontaneous movement of legs. Deep tendon reflexes: 1+ in right lower extremity, absent in left lower extremity and arms. Does not suck on gloved finger.</p> <p>Sensory: Flexes legs with noxious stimulation of the thighs.</p> <p>Labs: 09/21/YYYY: WBC 8.3, hemoglobin 12.1 (L), hematocrit 34.2 (L), platelet 71 (L), sodium 139, potassium 4.8, CO2 29, chloride 105, creatinine 0.25 (L), BUN 11</p> <p>Medications: Cefotaxime 155 mg 0.78 ml, every 12 hours Gentamicin 12.8 mg 1.26 ml every 24 hours Dextrose 10% 250 ml 8 ml/hr Dopamine 90 mg + Dextrose 5% 48 ml, 0.59 ml/hr Fat emulsion 20% 61 ml 1.29 ml/hr Sodium acetate 19.25 mEq + Heparin preservative free 250 units + water for inj 492.69 ml TPN – neonatal 500 ml Vitamin A-Vitamin D oint topical Zinc oxide topical 13% cream topical</p> <p>Bedside full head EEG- very abnormal with no evidence of brain activity (either spontaneous or elicited with stimulation). Extremely low voltage -1 uv throughout. Occasional sucking artifact. EKG lead artifact throughout.</p> <p>Assessment: Patient is DOL 6, born at 39 weeks, with persistent severe encephalopathy and global cerebral dysfunction, most likely from resolving edema and now necrosis from global ischemia. Neurological examination fluctuates and he exhibits only some brainstem function (and that which is present is not normal) and probable spinal withdrawal reflex to pain in legs. Hyponatremia has resolved and is not contributing to his abnormal exam. He is now well ventilated since reintubation, so this is not the etiology of abnormal brain function. Phenobarbital level is decreasing but has never been in a range that would cause altered mental status. Patient will not have recovery of brain function and I suspect if extubated, would not be able to maintain normal respiratory function.</p> <p>Plan: 1. Above discussed with NICU team and had been reviewed with family by our service last week. 2. There is no treatment for his neurological process. Ongoing dialogue with family to determine level of care desired for him.</p>	

DATE	FACILITY/ PROVIDER	MEDICAL EVENTS	BATES REF
09/21/YYYY	Provider/Hospital Name	<p>@1314 hours: EEG report:</p> <p>Reason for study: The patient is now a 5-day-old male with history of isoelectric EEG on September 18, 2015, as well as cerebral edema. There were initially concerns for seizure activity which have not persisted. The patient's examination is very abnormal with only some brainstem reflexes. Evaluate for change and electrographic activity.</p> <p>Medications: 1. Cefotaxime. 2. Gentamicin. 3. Dopamine.</p> <p>EEG Interpretation: As the tracing opens, the patient is noted to be very still with eyes closed. There is some occasional mouth chewing, sucking motions. Electrographic activity is minimal and is typically 1-1.5 microvolts in all areas. There is EKG lead artifact. There is no EMG artifact. There are no cortical rhythms. The only movement noted is the sucking artifact. There were no epileptiform abnormalities or areas of asymmetry. EKG lead was regular.</p> <p>Impression: This remains an isoelectric tracing without any changes compared to previous EEG.</p>	YH-20-CLT- YH-21-CLT
09/21/YYYY	Provider/Hospital Name	<p>@1352 hours: Ultrasound of head:</p> <p>Indication: 5-day-old newborn baby boy with history of respiratory distress, rule out intracranial hemorrhage.</p> <p>Impression: 1. No definitive evidence of intracranial hemorrhage. 2. A 4 mm choroid plexus cyst on the right.</p>	YH-368-AH- YH-370-AH
09/21/YYYY	Provider/Hospital Name	<p>@1455 hours: Neonatology Progress Notes:</p> <p>Physical examination: Weight is 3580 grams, up 30 grams. Vital Signs: 37, 138, 59/41 with a mean of 49. HEENT: Anterior fontanelle is soft and flat. Cardiovascular: Regular rate and rhythm, no murmur. Respirations: Equal air entry bilaterally, coarse basilar breath sounds, and spontaneous breaths. No increased work of breathing. Abdomen: Soft, nondistended with good bowel sounds. Neurologic: Sluggish pupil pinpoint on examination. Fluctuating corneal reflexes. Positive gag reflex. Occasional spontaneous sucking movements, baby does not make any other spontaneous purposeful movements.</p>	YH-147-AH- YH-148-AH

DATE	FACILITY/ PROVIDER	MEDICAL EVENTS	BATES REF
		<p>Respiratory: Objective: The baby is currently intubated on a rate of 20, tidal volume of 13, PEEP of 6, pressure support of 7 and I-time of 0.4. His PIPs ranged between 11-13. FiO2 requirement is 21%, saturations are between 95%-100%. Blood gas today was 7.46, 44, 85, 32, +8. Assessment: Guarded from a respiratory standpoint. Plan: Will decrease rate to 10 and will repeat blood gas at noon. Will obtain blood gases twice daily.</p> <p>Hematologic: Objective: CBC was checked today which is significant for anemia with a hematocrit of 34.2, platelet count was slightly decreased at 71. Assessment: Anemia, likely iatrogenic and thrombocytopenia due to initial birth insult. Plan: Will continue to follow as needed.</p> <p>Metabolic: Objective: Baby is currently nothing by mouth on D5. He has a UVC running D12 and intralipids for a total fluid of 80 ml/kg/d. He also has Dopamine running at 0.5 ml an hour. He has been kept nothing by mouth. He has a right arterial line with half sodium acetate at 0.5 ml an hour. Intake was 280, output was 289. Total fluid is 79 ml/kg/d. Urine output was 3.2 ml/kg/h and he has had 5 stools. Electrolytes were checked and were within normal limits and a bicarbonate of 29 and blood glucose of 86. Assessment: Stable Plan: Will continue nothing by mouth for now. Will increase fluid limit to 100 ml/kg/d. Will discontinue the Dopamine. We will continue to follow closely.</p> <p>Cardiovascular: Objective: The baby was started on Dopamine since birth to help wean perfusion. He is currently on 5 micrograms per kilogram per minute. Blood pressure has been ranging with MAPs between 50s-80s. Assessment: Stable. Plan: Will discontinue Dopamine and continue to follow blood pressures closely.</p> <p>Neurologic: Objective: Repeat EEG was obtained today, which continued to show low voltage. There were no cortical rhythms. There was no seizure activities noted. The baby's prognosis is poor. We discussed this with parents. Phenobarbital level was obtained today was 21.5. We will have a meeting with the parents today to discuss long-term outcomes and the plan to move towards extubation. We will discuss the possibility of obtaining do not resuscitate incase baby does not have spontaneous breaths once we extubate. We will also obtain an MRI for documentation of the extended of brain injury the baby has been in addition to the electroencephalogram which is extremely abnormal.</p>	

DATE	FACILITY/ PROVIDER	MEDICAL EVENTS	BATES REF
		<p>Infectious disease: Objective: The baby had a blood culture that was sent at birth which grew Escherichia coli which was sensitive to Gentamicin and Cefotaxime. The baby is currently on Gentamicin and Cefotaxime, day 5. Cefotaxime was added yesterday. Assessment: Stable from a sepsis standpoint Plan: Will discontinue Gentamicin and continue on Cefotaxime to complete 10-14 days of antibiotics.</p>	
09/21/YYYY	Provider/Hospital Name	<p>@2151 hours: MRI of brain without contrast:</p> <p>Clinical history: 5 days old male, encephalopathy.</p> <p>Impression: There is a tiny area of blooming on the gradient echo sequence in the left parietal lobe may represent punctate hemorrhage or calcification. No mass or evidence of acute infarct. Cerebral edema appears less prominent than on prior CT. Posterior scalp swelling/hematoma noted.</p> <p>Addendum: Heterogeneous signal on diffusion weighted images seen throughout both hemispheres compatible with mild diffuse heterogeneous cerebral ischemic changes. The ventricles and sulci are no longer effaced when compared to the recent CT scan of September 18, 2015, compatible with resolving cerebral edema.</p>	YH-367-AH- YH-368-AH, YH-30-AH- YH-31-AH
09/21/YYYY	Provider/Hospital Name	<p>Lab report:</p> <p>RBC 3.49 (L), Hemoglobin 12.1 (L), hematocrit 34.2 (L), platelet 71 (L)</p>	YH-385-AH- YH-386-AH
09/21/YYYY	Provider/Hospital Name	<p>Blood gases:</p> <p>pH 7.46 (H), pCO2 45, pO2 85, HCO3 32 (H), base excess 8 (H), O2 sat 97</p>	YH-392-AH
09/21/YYYY	Provider/Hospital Name	<p>CSF culture and gram stain:</p> <p>Source: CSF lumbar puncture Collected date: 09/18/YYYY</p> <p>Gram stain: Rare polymorphonuclear leukocytes No bacteria seen</p> <p>Final report: No growth</p>	YH-400-AH- YH-401-AH
09/21/YYYY	Provider/Hospital Name	<p>Lab report:</p> <p>Collected date: 09/16/YYYY</p>	YH-27-AH- YH-28-AH

DATE	FACILITY/ PROVIDER	MEDICAL EVENTS	BATES REF
		1. Adrenal Hyperplasia/(CAH)/17-OH-Progesterone 70.8 (out of range) 2. Adrenal Hyperplasia/(CAH)/17-OH-P extracted 20.5 (out of range)	
09/22/YYYY	Provider/Hospital Name	<p>@0900 hours: Pediatric Neurology Progress Notes:</p> <p>Chief complaint: Neonatal encephalopathy with cerebral edema. Had MRI brain last night. Reviewed and abnormal in addition to DWI diffuse abnormalities with left parietal evidence on GRE of blooming. Continues need for ventilatory support. No seizures reported. Has jerking eye movements to right and yawning.</p> <p>Medications: Cefotaxime 155 mg 0.78 ml, every 12 hours Dextrose 10% 250 ml 8 ml/hr Fat emulsion 20% 61 ml 1.29 ml/hr Sodium acetate 19.25 mEq + Heparin preservative free 250 units + water for inj 492.69 ml TPN – neonatal 500 ml Vitamin A-Vitamin D oint topical Zinc oxide topical 13% cream topical</p> <p>Objective: No qualifying data available, Vital signs 36.6, HR 124, BP 66/44 AFOF with large fontanelle.</p> <p>General: Severe distress. Eye: Pupils pinpoint with no obvious reactivity bilaterally. Periodic right horizontal jerk nystagmus. Present corneals bilateral. Present gag.</p> <p>Respiratory: Lungs are clear to auscultation. Cardiovascular: Normal rate. Gastrointestinal: Soft. Neurologic: Gag reflex normal, Normal deep tendon reflexes.</p> <p>Assessment and Plan: Diagnosis: Acute anoxic encephalopathy, brain MRI also shows abnormal thin corpus callosum suggesting a probable other underlying brain abnormality. Brain MRI DWI shows involvement of brainstem as well- edges of cerebral peduncles in midbrain.</p> <p>Yawning usually associated with diffuse cerebral cortical dysfunction. Despite presence of some brainstem activity. Prognosis remains grim. Discussed with RN and Dr. Moorthy.</p>	YH-129-AH- YH-131-AH
09/22/YYYY	Provider/Hospital Name	<p>@1447 hours: Neonatology Progress Notes:</p> <p>Physical examination: Weight is 3630 grams, up 50 grams. Vital Signs: 36.6, 123, 34, 67/40 with a mean of 54.</p>	YH-146-AH- YH-147-AH

DATE	FACILITY/ PROVIDER	MEDICAL EVENTS	BATES REF
		<p>HEENT: Anterior fontanelle soft and flat. Pupils remain pinpoint with no reactivity to light. There is horizontal nystagmus seen bilaterally deviating towards the right. Absent corneal reflexes on examination. The baby does make spontaneous sucking and yawning movements.</p> <p>Cardiovascular: Regular rate and rhythm, no murmur.</p> <p>Respirations: Equal air entry bilaterally.</p> <p>Abdomen: Soft, nondistended. Good bowel sounds.</p> <p>Neurologic: Decreased tone for gestational age.</p> <p>Respiratory: Objective: The baby remains intubated on a rate of 10, tidal volume of 13/6, pressure support of 7. I-time of 0.4, saturating between 94% - 100%. He is on room air. Assessment: Stable with spontaneous breath. Plan: Will continue to keep baby intubated for now.</p> <p>Metabolic: Objective: The baby remains nothing by mouth. He has a UVC running D12 Hal and Intralipids. He also has a radial arterial line running 1/4 normal saline at 0.5 ml/h. Total fluid is 104 kcal/kg/d. Urine output was 1.4 ml/kg/h and he has had 5 stools. Blood glucose was stable at 100. He had a Phenobarbital level which was 17.6. Assessment: Stable. Plan: Will start feeds of Enfamil/EBM at 10 ml every 3 hours. Will increase fluid limit to 120. Will obtain a G7, CBC and a triglyceride in the morning.</p> <p>Infectious disease: Objective: The baby had a positive blood culture at growth. Repeat blood cultures have remained negative. He is currently on Cefotaxime. Today will be day 6 of treatment. Assessment: Stable. Plan: We will continue Cefotaxime until the baby completes of 14 days of intravenous antibiotics.</p>	
09/22/YYYY	Provider/Hospital Name	<p>@1851 hours: Lactation Progress Notes:</p> <p>Mom's insurance Amerihealth, & per case management delivered a Medela pump in style to her. She signed contract & I faxed her information to superior oxygen. Also pumped here w symphony. Infant born at MOH 9/16/15 by SVD at 39+2wks. BW 3165 gm = 71bs 0oz. Apgars2 & 7. Instructed mom how to use symphony & obs her pumping w #24 flanges which were appropriate. Explained PIS, & how to use & to leave symphony parts here, & take PIS ones home. Obtained several cc's.</p>	YH-218-AH
09/22/YYYY	Provider/Hospital Name	<p>Lab report:</p> <p>Creatinine 0.25 (L), sodium 139, potassium 4.8, CO2 29</p>	YH-377-AH- YH-378-AH
09/23/YYYY	Provider/Hospital	<p>@0941 hours: Pediatric Neurology Progress Notes:</p>	YH-127-AH-

DATE	FACILITY/ PROVIDER	MEDICAL EVENTS	BATES REF
	Name	<p>Chief complaint: No significant changes overnight. No reports of any seizure- nor secure like activity.</p> <p>Medications: Cefotaxime 155 mg 0.78 ml, every 12 hours Dextrose 10% 250 ml 8 ml/hr Fat emulsion 20% 77 ml 1.94 ml/hr Sodium acetate 19.25 mEq + Heparin preservative free 250 units + water for inj 492.69 ml TPN – neonatal 500 ml Vitamin A-Vitamin D oint topical</p> <p>Objective: No qualifying data available, Vital signs 36.1, HR 136, RR 37, BP 44/28, head circumference 36 cm.</p> <p>General: Remains intubated. Eye: Pupils remain pinpoint with no obvious reactivity to light. Respiratory: Lungs are clear to auscultation. Cardiovascular: Normal rate. Gastrointestinal: Soft, non-tender, non-distended, no organomegaly. Neurologic: Normal motor function. Gag reflex normal, roving eye movements with occasional downbeat and right horizontal nystagmus. Increased right DTRs over left, but with obvious extreme cross adductors not just in LE, but with obvious right hamstring flexion with left slight tap of left brachioradialis and nearly violent LUE jerk reflex with slight tap of right brachioradialis. Present gag. Present corneals bilateral.</p> <p>Labs: WBC 8.5 Low: RBC 3.41, hemoglobin 11.6, hematocrit 32.9, platelet 119, potassium 3.9</p> <p>Assessment and Plan: Diagnosis: Acute anoxic encephalopathy, DOL 7 in male with possible HIE and concern for possible neurometabolic concurrent encephalopathy with isoelectric EEG. Suggest follow up on urine organic acids, serum amino acids. Suggest repeat peripheral lactate. Add serum gastrin, consider repeating LP for further testing (NTS?) Reviewed how CT scan on head from 9/18 shows edema that is not seen on brain MRI from 9/21. Unsure what changed and how so fast? Might neuroradiology have an opinion on this? Will re-review chart and discuss with team. Either way, prognosis at this point still appears to be grim. Discussed with Drs. Moorthy and Shapiro.</p>	YH-129-AH
09/23/YYYY	Provider/Hospital	@1300 hours: Procedure Report:	YH-200-AH

DATE	FACILITY/ PROVIDER	MEDICAL EVENTS	BATES REF
	Name	<p>Procedure: NICU central line removal</p> <p>Confirmed plan of removal Catheter checked and was intact</p>	
09/23/YYYY	Provider/Hospital Name	<p>@1502 hours: Neonatology Progress Notes:</p> <p>Physical examination: Weight is 3700 grams, up 70 grams. Vital Signs: 37.6, 136, 37, 44/28 with a mean of 36. HEENT: Anterior fontanelle soft and flat. Pupils continue to be myotic bilaterally with no reaction to light. There is horizontal and downward nystagmus seen. Corneal reflex examination fluctuating. Baby does have spontaneous suck and continues to exhibit multiple yawning-like episodes. There have not been any spontaneous movements. Cardiovascular: Regular rate and rhythm, no murmur. Respirations: Equal air entry bilaterally. ET tubs still in place. No increased work of breathing. Abdomen: Soft, nondistended. Good bowel sounds. Neurologic: Hyperreflexia on examination. Tone is normal for gestational age. Baby continues to have abnormal neurologic examination with pupils that are constricted and not reactive to light, downwards and horizontal nystagmus. Good spanking movements, sucking movements and yawn-like movements. No seizure-like activity besides those described above.</p> <p>Respiratory: Objective: Baby remains intubated on SIMV 10, tidal volume of 13/6, pressure support of 7. Saturations between 97%-100%. His blood gas this morning was 7. 41/41/95/26. Assessment: Stable with spontaneous breath with spontaneous breath. Plan: Will extubate to room air today and will follow clinically. If baby deteriorates at this point, we will reintubate and continue to provide support as needed.</p> <p>Hematologic: Objective: Mild anemia noted on today's CBC with hematocrit of 32.9. I/T ratio remains 0 and platelet count of 119. Assessment: Stable. Plan: Will continue to follow as needed.</p> <p>Metabolic: Objective: Feeds were started yesterday. Baby is currently on Enfamil 10 ml every 3 hours with minimal aspirates. He still has UAC and right radial line. UAC currently running D13 Hal, fluid limit of 110 kcal/kg/d. Urine output has been stable at 3.8 ml/kg/h and he has had 3 stools. Electrolytes were checked and were within normal limits. Assessment: Stable from metabolic standpoint. Plan: Will increase feeds to 20 ml every 3 hours. Will discontinue</p>	YH-144-AH- YH-146-AH

DATE	FACILITY/ PROVIDER	MEDICAL EVENTS	BATES REF
		<p>UVC and start PIV and continue peripheral hyperalimentation. Will repeat EMF tomorrow. Will increase fluid limit to 130 ml/kg/d.</p> <p>Infectious disease: Objective: Baby has been started on Cefotaxime since admission due to Escherichia coli sepsis. Today is day 5/10 of antibiotic treatment. Repeat blood culture which was drawn on September 18, 2015, remains negative. Assessment: Stable. Plan: We will continue to complete 10 days of antibiotics.</p>	
09/23/YYYY	Provider/Hospital Name	<p>Lab report:</p> <p>RBC 3.41 (L), Hemoglobin 11.6 (L), hematocrit 32.9 (L), platelet 119 (L)</p>	YH-385-AH- YH-386-AH
09/23/YYYY	Provider/Hospital Name	<p>Blood gases:</p> <p>pH 7.37, pCO2 43, pO2 71 (L), HCO3 25, O2 sat 93 (L)</p>	YH-391-AH
09/23/YYYY	Provider/Hospital Name	<p>Lab report:</p> <p>Gastrin 162</p> <p>Aminoacid: Asparagine 84 (H), Alpha-amino adipic acid 8 (H), Beta-alanine 10 (H), Ethanolamine <4 (L), alpha-amino butyric acid 26 (H), Valium 335 (H), Methionine 60 (H), Isoleucine 137 (H), Leucine 210 (H), Phenylalanine 88 (H), Lysine 262 (H)</p>	YH-378-AH- YH-380-AH
09/24/YYYY	Provider/Hospital Name	<p>@0800 hours: NICU Speech Therapy Evaluation/Infant feeding evaluation: (<i>Illegible Notes</i>)</p> <p>SLP oral assessment: Oral mucosa moist. Labial, mandible – within normal limits Palate – Rounded Lingual – Pink/healthy</p> <p>SLP oral motor assessment: Mandible – opened easily Lingual – adequate lingual cupping Pressure – Functional Pattern – established consecutive sucks Pacifier – Loss after approx. 10 # of sucks Nutritive suck – Detached nipple Nutrition – Enfamil newborn, consistency thin Position – upright, cradle Establishment – 10-20 seconds, detached ____ Pressure – Functional ____ Bolus transfer – Adequate Amount consumed – 7cc trial via detached ____ bottle</p>	YH-406-AH- YH-410-AH

DATE	FACILITY/ PROVIDER	MEDICAL EVENTS	BATES REF
		<p>Duration of feeding – 20 min</p> <p>Response to feeding: Hiccups</p> <p>Assessment: Oral dysphagia characterized by poor oral organization Feeding difficulty characterized by poor oral intake/fatigue</p> <p>Treatment indicated for: Oral dysphagia, feeding difficulties</p> <p>Prognosis: Good</p>	
09/24/YYYY	Provider/Hospital Name	<p>@1030 hours: OT initial evaluation: (<i>Illegible Notes</i>)</p> <p>Assessment: Patient presents with ___ edema that affects patient's tone ___</p> <p>Plan: Continue skilled interventions 5 times/week for 12 weeks.</p> <p>Additional comments: Patient presents with edema that effects patient's ROM and ___ evaluation. Patient had ___ ROM in left elbow and bilateral knees but it is ___ patient's edema impacts this. Patient will benefit from OT ___.</p>	YH-403-AH- YH-405-AH
09/24/YYYY	Provider/Hospital Name	<p>@1435 hours: Pediatric Neurology Progress Notes:</p> <p>Subjective: Patient extubated to room air on 9/23 around 10 AM. Has remained on room air. Breathing comfortably. Speech therapist saw him and he was able to nipple and swallow 7 ml of milk without coughing or choking. No abnormal movements.</p> <p>Objective: Patient examined at approx. 9:15AM</p> <p>General: Patient is moving spontaneously, opening his eyes, and looking around. Some yawning- not as prominent. Has hiccups. Has IV board on right arm. NG tube in place. Anterior fontanelle was full but soft. No splaying of sutures. Head Circumference (HC) 35.5 cm.</p> <p>Heart: Regular rate and rhythm.</p> <p>Lungs: Clear bilaterally.</p> <p>Abdomen: Soft, non distended, no palpable masses or Hepatosplenomegaly.</p> <p>Extremities: Well perfused. No edema. One bruise on left knee.</p> <p>Neurologic: Cranial nerves: Right pupil is still slightly larger than the left but they are both briskly reactive. Will occasionally have a conjugate gaze and looks around in various directions spontaneously. Otherwise, has the bilateral down beating nystagmus. Corneal reflexes absent- he doesn't appear to mind these being testing. Gag reflex consistently present and he coughs with this. Symmetric and intact facial grimace that was consistent. No spontaneous chewing movements today.</p> <p>Motor: Brings left hand up to his mouth but doesn't suck on it. Arms and legs are in a flexion type of posture. Tone in extremities is normal today. Significant head lag on traction though. Slips through on</p>	YH-125-AH- YH-127-AH

DATE	FACILITY/ PROVIDER	MEDICAL EVENTS	BATES REF
		<p>vertical suspension but flexes his knees. Did not check horizontal suspension due to NG tube and IV tubing.</p> <p>Deep tendon reflexes: 2+ in lower extremities, with crossed adduction to left leg with tapping on right patellar. With assessment of reflexes in the left extremity, both pale liars are elicited in overflow of reflexes. Unable to assess right upper extremity due to IV board.</p> <p>Sensory: Flexes legs with noxious stimulation of the thighs and squirms upper body and moves arm with this - no crying or grimacing though.</p> <p>Labs: Sodium 140, potassium 4.1, CO2 25, chloride 110, creatinine <0.20 (L), BUN 12, glucose 84</p> <p>Medications: Cefotaxime 155 mg 0.78 ml, every 12 hours Vitamin A-Vitamin D oint topical Zinc oxide topical 13% cream 60 g topical</p> <p>Brain MR images personally viewed with Dr. Altman in neuro radiology. He agrees that there are significant, bilateral abnormalities on diffusion weighted imaging and ADC maps consistent with global hypoxia. The basal ganglia do not seem to be effected. There is some involvement of the brainstem at the level of the midbrain. Small hemorrhage in the left parietal lobe. No hydrocephalus or ventriculomegaly.</p> <p>Pending labs: Urine organic acids, serum and CSF amino acids, serum gastrin.</p> <p>Assessment: Patient is DOL 8. Born at 39 weeks, with persistent severe encephalopathy and global cerebral dysfunction and imaging consistent with global ischemia. Discussed MRI with neuroradiology and images were compared to the head CT done 3 days prior. The resolution of the cerebral edema over this time course was thought to be expected and not unusual.</p> <p>Neurological examination continues to fluctuate with improvement of areas of brainstem functioning- mainly lower brainstem as he is consistently gagging and able to swallow and clear oral secretions. The unusual eye movements are consistent with upgaze dysfunction from midbrain involvement, but this was variable today. Patient is clearly more alert and moving spontaneously and reactively (although no crying). So far, has tolerated extubation very well. Per NICU's discussion with the family, they are wanting full care and support. Baby is showing some improvements today, although his neurological exam is still quite abnormal.</p> <p>Plan: 1. Radiology will be working on an addendum to the previous report</p>	

DATE	FACILITY/ PROVIDER	MEDICAL EVENTS	BATES REF
		<p>which did not report the findings on DWI or ADC.</p> <p>2. Given the change in neurologic function, an EEG would be helpful to assess for any recovery of cortical rhythms.</p> <p>Plan was discussed with Dr. Rouhani who was also present during my examination.</p>	
09/24/YYYY	Provider/Hospital Name	<p>@1731 hours: Neonatology Progress Notes:</p> <p>Day of life: 8.</p> <p>Physical examination: Weight today is 3720, up 20 grams. Vital signs: Temperature 36.6, heart rate 122, respiratory rate 47, blood pressure 54/29 with a mean of 42. Lungs: Clear to auscultation bilaterally with no retractions and comfortable work of breathing. Heart: Regular rate and rhythm with no murmur. Pulses are normal. Abdomen: Soft and nondistended with normal bowel sounds and no hepatosplenomegaly. Skin: Well perfused with no rashes or lesions. Neurologic: The baby is awake, opening eyes and moving all extremities. His tone seems to be appropriate. He is hyperreflexic. His pupils are sluggish, but reactive to light bilaterally. Please see the Neurology's note for complete neurologic examination.</p> <p>Respiratory: Objective: The baby was extubated yesterday and has remained on room air with comfortable work of breathing with normal saturations. His blood gas this morning had a pH of 7.39, pCO₂ of 41 and a bicarbonate of 25. Assessment: Stable respiratory status. Plan: Continue with clinical observation. We will discontinue his every 12 hour blood gases.</p> <p>Infectious disease: Objective: The baby is on Cefotaxime for Escherichia coli bacteremia. Today is day 6 of a 10-day course after the negative culture. However, he has had difficulty with maintaining the PIV. Assessment: On antibiotics with negative followup culture. Plan: Continue with antibiotics to finish a 10-day course. I have talked to Dr. Patel who recommended putting the baby on Ceftriaxone IM on 1 dosing to finish the 10-day course.</p> <p>Hematologic: Objective: The baby has stable anemia and thrombocytopenia. There is a CBC scheduled for tomorrow morning. Assessment: Stable CBC with borderline hematocrit and platelet count Plan: Follow the CBC tomorrow. We will consider transfusion if</p>	YH-143-AH- YH-144-AH

DATE	FACILITY/ PROVIDER	MEDICAL EVENTS	BATES REF
		<p>clinically indicated.</p> <p>Metabolic: Objective: The baby is on Enfamil or breast milk at 30 ml every 3 hours. His IV infiltrated early this morning. He is also getting quarter sodium chloride at 0.5 ml an hour via the radial arterial line. His total intake was 81 ml/kg/d with urine output of 3.3 ml/kg/h and 2 stools. His electrolytes this morning are normal with a sodium of 140, potassium of 4.1, chloride 110, bicarbonate 25, BUN 12, creatinine less than 0.2 and a calcium of 9.2. His glucose is 84. Assessment: Tolerating feeds. Plan: Increase his feeding volume to 40 ml. We will also get the Feeding Team to work on introducing bottle feeding. We will also pull his arterial line and discontinue the A-line fluid.</p> <p>Neurologic: Objective: Dr. Khara from Pediatric Neurology was here this morning to see the patient. She recommended doing a followup EEG. This is scheduled for early tomorrow morning. The MRI that was done yesterday is being re-read by a Pediatric Neuroradiologist in conjunction with Pediatric Neurology. The extensive labs sent for workup of metabolic disease and endocrine issues are pending.</p>	
09/24/YYYY	Provider/Hospital Name	<p>Lab report:</p> <p>Creatinine <0.20 (L), sodium 140, potassium 4.1, chloride 110 (H), CO2 25</p>	YH-377-AH- YH-378-AH
09/24/YYYY	Provider/Hospital Name	<p>Blood gases:</p> <p>pH 7.39, pCO2 41, pO2 74 (L), HCO3 25, O2 sat 94 (L)</p>	YH-391-AH
09/25/YYYY	Provider/Hospital Name	<p>@1100 hours: EEG report:</p> <p>History: This is a 9-day old with marked neonatal encephalopathy with CT imaging demonstrating diffuse cerebral injury and previous EEG demonstrating isoelectric appearance.</p> <p>Medications: Ceftriaxone.</p> <p>Interpretation: As the tracing opens, the baby is noted to be asleep. The eyes are closed. Prominent EMG artifact is noted. The dominant cortical rhythm identified is a generalized, a low-amplitude, suppressed appearing fast rhythm. This is interrupted at times by respiratory artifact seen over the right hemisphere. In addition; at times semi rhythmic 3-4 Hz theta is noted over the frontal region. Frontal sharp EEG transients are also identified. Excessive sharp waves are noted over the right temporal region. With stimulation, further EMG artifact is identified, but there is no clear change in the background rhythm. EKG demonstrated a regular rhythm.</p>	YH-18-REF

DATE	FACILITY/ PROVIDER	MEDICAL EVENTS	BATES REF
		<p>Impression: This remains an abnormal tracing due to the following:</p> <ol style="list-style-type: none"> 1. Diffuse cortical suppression with occasional 3-4 Hz theta activity identified over the frontal regions bilaterally. 2. Lack of reactivity. 3. Excessive sharp EEG transients identified over the right temporal region. 4. Unusual appearing frontal sharp waves that cannot be clearly distinguished from encoche frontale. <p>While this tracing does represent improvement from the patient's prior tracing, it remains significantly abnormal and is suggestive of diffuse cortical injury.</p>	
09/25/YYYY	Provider/Hospital Name	<p>@1813 hours: Neonatology Progress Notes:</p> <p>Day of life: 9</p> <p>Physical examination: Weight 3594, down 126 grams. Vital Signs: 36.6, 160, 62, 73/46 with a mean of 55. HEENT: Anterior fontanelle soft and flat. Chest: Clear. Cardiac: Regular without murmur. Abdomen: Soft. There is no tenderness or distention. Neurologic: Reveals depressed gag. Corneal reflexes are present but not brisk. There is a disorganized suck which is not sustained. Extraocular muscles are intact. The pupils are reactive and symmetric. There is a nystagmoid movement of the eyes with what appears to be a fast beat to the right. Deep tendon reflexes are present and symmetric.</p> <p>Respiratory: Objective: Saturations 97%-99% in room air. No problems with his respiratory effort. Assessment: No lung disease and he is breathing regularly. Plan: Continue to monitor. He continues to be at risk because of brainstem injury.</p> <p>Infection: Objective: He is on Ceftriaxone completing a 10-day course for uncomplicated E. coli bacteremia. Plan: We will complete 10 days with 3 more daily doses of Ceftriaxone intramuscularly.</p> <p>Hematologic: Objective: Hemoglobin and hematocrit 12.9 and 36.7, I/T 0.05, platelets 272,000. Assessment: As his excess fluid is unloading, his hematocrit rising back to a more realistic value.</p>	YH-142-AH- YH-143-AH

DATE	FACILITY/ PROVIDER	MEDICAL EVENTS	BATES REF
		<p>Plan: We will continue to monitor CBCs intermittently.</p> <p>Metabolic: Objective: The baby is on Enfamil or breast milk. Mother has not provided any significant quantities of breast milk yet The baby is receiving 40 ml every 3 hours and had 97 ml and 65 kcal/kg/d yesterday with a urine output of 4.4 ml/kg/h and 3 stools. Assessment: Stable, needs more fluid. Plan: Increase feeds to 50 ml every 3 hours.</p> <p>Neurologic: Objective: His neurologic examination remains grossly abnormal. EEG was done today and is also abnormal, but formal interpretation is still pending. Assessment: Hypoxic ischemic encephalopathy with a very high likelihood of severe neurodevelopmental disability as a consequence. Plan: Continue to monitor examinations and work in concert with Pediatric Neurology.</p>	
09/25/YYYY	Provider/Hospital Name	<p>Lab report: Hemoglobin 12.9 (L), hematocrit 36.7 (L), platelet 272</p>	YH-385-AH- YH-386-AH
09/26/YYYY	Provider/Hospital Name	<p>@1352 hours: Neonatology Progress Notes:</p> <p>Day of life: 10</p> <p>Physical examination: Weight 3504, down 90 grams. Vital Signs: 37, 136, 52, 71/45 with a mean of 59. HEENT: Anterior fontanelle soft and flat. Chest: Clear. The baby is pink in room air. He is somewhat alert today and does seem to briefly fix and follow. His neurologic examination is otherwise unchanged. He does have a gag, although it is slightly depressed and he is not demonstrating nystagmus at the time of my examination. Abdomen: Soft with active bowel sounds. Neuromuscular tone is slightly increased in the lower extremities, particularly in the hip girdle area.</p> <p>Respiratory: Objective: Pink in room air. No problems, saturations 97%-99%. Plan: Follow.</p> <p>Infection: Objective: He is on Ceftriaxone for Escherichia coli sepsis. This is day 8 of 10 of antibiotic therapy. Plan: Two more doses of intramuscular ceftriaxone and that will complete his course.</p> <p>Metabolic:</p>	YH-141-AH- YH-142-AH

DATE	FACILITY/ PROVIDER	MEDICAL EVENTS	BATES REF
		<p>Objective: He is on Enfamil or breast milk 50 ml every 3 hours, tolerating feeds well and today he actually nipped an entire feeding without any significant difficulty. He had 103 ml and 68 kcal/kg/d yesterday with a urine output of 3.4 ml/kg/h and 6 stools. Mother has not provided any breast milk as yet and I suspect that she is not pumping. We will discuss with her.</p> <p>Plan: We will increase feeds to 60 ml every 3 hours, which is about 130 ml/kg/d and continue to monitor for weight gain. Thus far I think the baby has been unloading the additional fluid that he acquired during his acute illness.</p>	
09/27/YYYY	Provider/Hospital Name	<p>@1729 hours: Neonatology Progress Notes:</p> <p>Day of life: 11</p> <p>Physical examination: Weight 3344, down 160 grams. Vital Signs: 36.9, 135, 56, 67/42 with a mean of 50. Head: Anterior fontanelle soft and flat. Chest: Clear. There is no murmur. Pulses are 2+ Neuromuscular: Tone is beginning to feel as though it is increasing. Neurologic: Cranial nerve examination is essentially unchanged. Pupils are reactive. There is a gag and there are corneal reflexes.</p> <p>Respiratory: Objective: No issues, saturations 99%. Plan: Continue to monitor.</p> <p>Infection: Objective: He continues on Ceftriaxone. Today is day 9 of 10 of therapy and tomorrow will be his last dose of Ceftriaxone. Plan: Complete his antibiotic course.</p> <p>Metabolic: Objective: He is on Enfamil mostly. Mother has not brought any breast milk. He is receiving 60 ml every 3 hours and he took all of his feeds by mouth in the last 24 hours. He took 126 ml and 83 kcal/kg/d yesterday with urine output of 5 ml/kg/h and he had 6 stools. Assessment: He continues to lose weight, probably unloading all of the additional fluid he retained during his critical illness and cooling phase. Plan: Will give trial of as-desired feeds on an every 3 hour basis with a minimum 60 ml and monitor closely.</p>	YH-140-AH- YH-141-AH
09/28/YYYY	Provider/Hospital Name	<p>@1758 hours: Vaccination record:</p> <p>Age 12 days</p> <p>Hepatitis B – 10 mcg in right thigh</p>	YP-2-REF, YH-813-AH
09/28/YYYY	Provider/Hospital	@1917 hours: Neonatology Progress Notes:	YH-139-AH-

DATE	FACILITY/ PROVIDER	MEDICAL EVENTS	BATES REF
	Name	<p>Day of life: 12</p> <p>Physical examination: Weight 3314, down 30 grams. Vital Signs: 36.8, 158, 52, 85/43 with a mean of 55. Head: Anterior fontanelle soft and flat, moist mucous membranes. Lungs: Clear. Heart: Regular rate and rhythm without murmur. Abdomen: Soft, nontender, nondistended with good bowel sounds. Neurologic: Quiet but alert. When agitated, movements are a little jerky. The baby has a normal suck.</p> <p>Metabolic: Objective: Baby is taking feeds of Enfamil with iron ad lib every 3 hours. She is taking 60-90 ml per feed. Total fluids 166 ml/kg/d equal 110 kcal/kg/d, Urine output 5.2 ml/kg/ h with 1 stool. Assessment: Tolerating feeds, but would like to see consistent intake and weight gain on ad-lib schedule. Plan: We will continue current feeds and monitor intake and weight gain closely. May need to increase caloric density of feeds if weight gain does not improve.</p> <p>Respiratory: Objective: Baby remains stable in room air with saturations of greater than 96%. Assessment: Stable respiratory status. Plan: Continue close monitoring.</p> <p>Infectious: Objective: Today is day 10 of 10 with ceftriaxone for Escherichia coli sepsis with negative culture. Assessment: Sepsis, resolving. Plan: Will complete today's doses of antibiotic therapy. Will also order hepatitis B vaccine to be given after parental consent.</p> <p>Neurologic: Objective: The baby's neurologic examination remains unchanged. The serum gastrin level was 162. A 17-hydroxyprogesterone level may be back by tomorrow. Urine organic acids, serum amino acids and CSF amino acids are still pending and will not be back for few more days. Assessment: Status post perinatal asphyxia and Escherichia coli sepsis. Plan: Will need outpatient followup with Pediatric Neurology. No additional imaging studies at this time.</p>	YH-140-AH
09/29/YYYY	Provider/Hospital Name	<p>@1456 hours: Neonatology Progress Notes:</p> <p>Day of life: 13</p>	YH-138-AH- YH-139-AH

DATE	FACILITY/ PROVIDER	MEDICAL EVENTS	BATES REF
		<p>Physical examination: Weight 3327, up to 13 grams. Vital Signs: 36.5, 152, 50, 81/41 with a mean of 54. Head: Anterior fontanelle soft and flat, moist mucous membranes. Lungs: Clear. Heart: Regular rate and rhythm without murmur. Abdomen: Soft, nontender, nondistended with good bowel sounds. Neurologic: Quiet and alert.</p> <p>Metabolic: Objective: Baby is taking feeds of Enfamil with iron ad lib. He is taking 60-80 ml per feed. Total fluids 161 ml/kg/d equal 107 kcal/kg/d. Urine output 5.6 ml/kg/h with 5 stools. Assessment: Tolerating feeds well and starting to gain weight Plan: Continue to monitor closely and if he continues to gain weight should be ready for discharge.</p> <p>Respiratory: Objective: Baby remains stable in room air. Assessment: Stable respiratory status. Plan: Continue close monitoring.</p> <p>Infectious: Objective: Baby has finished his 10-day course of antibiotic therapy with negative cultures for Escherichia coli sepsis yesterday. Assessment: Resolved sepsis. Plan: No additional therapy at this time.</p> <p>Neurologic: Objective: The baby has significant abnormality on MRI. The EEG has been persistently abnormal. Assessment: At high risk for encephalopathy and long-term neurologic sequelae. Plan: He will have close outpatient followup with Early Intervention Services and Pediatric Neurology.</p>	
09/30/YYYY	Provider/Hospital Name	<p>@1625 hours: Newborn Hearing Screen:</p> <p>Hearing screens were performed on the infant using auditory brainstem response testing. Both ears were tested simultaneously at 35 dB with the Algo 3 Newborn Hearing Screener. This infant did not pass the screening test. These results do not necessarily indicate permanent hearing loss, but do denote that normal auditory response was not present at the required confidence level at the time of screening. Infants who do not pass the initial screen should complete additional audiological evaluation prior to the age of three months.</p>	YH-154-AH
09/30/YYYY	Provider/Hospital Name	<p>@1911 hours: Neonatology Progress Notes:</p> <p>Day of life: 14.</p>	YH-138-AH

DATE	FACILITY/ PROVIDER	MEDICAL EVENTS	BATES REF
		<p>Physical examination: Weight 3227 grams, down 100 grams. Length 53 cm. Head circumference 35.5 cm. Vital Signs 37.1, 137, 44, 81/53 with a mean of 61. HEENT: Anterior fontanelle is soft and flat, moist mucous membranes. Lungs: Clear. Heart: Regular rate and rhythm without murmur. Abdomen: Soft, nontender, nondistended with good bowel sounds. Neurologic: Asleep in partial flexion.</p> <p>Metabolic: Objective: Baby is taking feeds of Enfamil with iron ad lib. He is taking 50-80 ml per feed, but this is increased with a change in the brand of nipple. Total fluids 126 ml/kg/d equal 83 cal/kg/d. Urine output 4.2 ml/kg/h with 3 stools. Assessment: Concerned about the baby's intake and lack of weight gain. Plan: Will continue to have feeding team work with the baby with the new nipple and will advance the feedings to Enficare 22 calorie feeds.</p> <p>Respiratory: Objective: Baby remains stable in room air. Assessment: Stable respiratory status. Plan: Continue close monitoring.</p>	
10/01/YYYY	Provider/Hospital Name	<p>@1427 hours: Neonatology Progress Notes:</p> <p>Day of life: 15</p> <p>Physical examination: Weight 3213 grams, down 14 grams Vital Signs 37.3, 160, 40, 77/49 with a mean of 54. HEENT: Anterior fontanelle is soft and flat Cardiovascular: Regular rate and rhythm, no murmur. Respirations: Equal air entry bilaterally. Abdomen: Soft, nondistended. Good bowel sounds. Neurologic: Slightly increased tone for gestational age. Pupils are reactive to light. Good suck and swallow.</p> <p>Respiratory: Objective: Respirations remains stable in room air with no documented events. Assessment: Stable. Plan: Will follow closely.</p> <p>Metabolic: Objective: The baby is getting Enficare 22 calories ad lib taking between 70-120 ml per feed. Intake was 167 ml/kg/d. Urine output</p>	YH-137-AH

DATE	FACILITY/ PROVIDER	MEDICAL EVENTS	BATES REF
		<p>was 5.9 ml/kg/h and he has had 4 stools. Assessment: Tolerating feeds well. Plan: Will make feeds every 3 hours as opposed to 3-4 hours as it is right now due to baby's current weight loss. We will continue to follow closely.</p>	
10/02/YYYY	Provider/Hospital Name	<p>@1240 hours: Neonatology Progress Notes:</p> <p>Day of life: 16</p> <p>Physical examination: Weight 3263 grams, up 50 grams Vital Signs 36.9, 165, 55, 82/48 with a mean of 59. HEENT: Anterior fontanelle is soft and flat Chest: Clear, good air entry, no retractions. Cardiovascular: No murmur. Abdomen: Soft, without distention. Bowel sounds are present. Neurologic: Tone is slightly increased.</p> <p>Metabolic: Objective: Baby is taking Enfacare 22 ad lib every 3 hours. He is taking 60-95 ml. Intake was 171 ml/kg/d and 125 kcal/kg/d. Urine output was 5.7 ml/kg/h. There were 3 stools yesterday. Baby was placed on every 3-hour feeds yesterday. He has been on ad lib feeds now since May 27, 2015, but this is the first day that he gained weight. Plan: Continue Enfacare 22 ad lib every 3 hours. Monitor intake and weight gain.</p> <p>Neurologic: Objective: Doing well. Plan: We will arrange for followup with Pediatric Neurology after discharge.</p> <p>Discharge planning: I anticipate discharge in the next 24-72 hours, if he continues to gain weight.</p>	YH-136-AH- YH-137-AH
10/02/YYYY	Provider/Hospital Name	<p>Prescription Record:</p> <p>Outpatient speech therapy feeding evaluation and treatment Diagnosis: Feeding difficulty</p>	WPR-58-AH
10/02/YYYY	Provider/Hospital Name	<p>NICU SLP/Feeding Final Progress Notes: (Illegible Notes)</p> <p>Treatment dates: 09/25/YYYY, 09/28/YYYY, 09/30/YYYY, 10/01/YYYY</p> <p>Signs of stability: ____ stable, hypotonic, alert</p> <p>Signs of feeding readiness: Rooting, sucking, hands to mouth. Q score 3</p>	YH-434-AH- YH-438-AH, YH-411-AH- YH-414-AH, YH-419-AH- YH-422-AH, YH-427-AH- YH-433-AH, YH-441-AH-

DATE	FACILITY/ PROVIDER	MEDICAL EVENTS	BATES REF
		<p>Treatment completed: Feeding: Enfamil Feeding position: Upright Nipple used: ___ Suck swallow breath pattern: Alternating Oral motor skills with nutritive sucks: Tongue cupping, lingual seal (weak seal ___with audible ___) Anterior loss: None</p> <p>Assessment: Impairment and limitation: Neuro impairment Continue skilled intervention to address: Stability of suck swallow breath pattern, parent education, promote adequate feeding skills, determine feeding pattern.</p> <p>Strong NNS noted with increased loss and increased audible break in lingual seal noted with decreased efficiency. Baby consumed 80 cc in 25 minutes. Began in coordinated SSB but as feed progressed, intermittent, then alternate SSB noted. New goals: #2: Increase lingual cupping to decrease anterior loss to <10% of feed. #3: Increase lingual seal to decrease audible break in seal to <10 ___/feed</p> <p>Prognosis for therapy: Fair</p> <p>Plan: Continue skilled intervention 4x/week for 6 weeks</p>	YH-446-AH
10/02/YYYY	Provider/Hospital Name	<p>NICU OT Final Progress Notes:</p> <p>Treatment dates: 09/25/YYYY, 09/28/YYYY, 09/29/YYYY, 09/30/YYYY</p> <p>Behavior state: Light sleep -> Slightly awake -> wide awake</p> <p>Signs of stress: Increased muscle tone, spastic movements, yawning</p> <p>Treatment completed: PROM. Tolerance indicators: Increased muscle tone with ___ Targeting areas: Increased right lateral head ___movement of extremities at times. Unable to get full range in bilateral hips, knee and ankle Tolerated tactile stimulation fairly well with stable vitals</p> <p>Assessment: Impairment: Increased tone, poor tactile stimulation tolerance Patient ongoing with OT goals. Plan: Continue skilled interventions 5x/week for 1 week</p>	YH-439-AH- YH-440-AH, YH-415-AH- YH-418-AH, YH-423-AH- YH-426-AH
10/03/YYYY	Provider/Hospital Name	<p>Neonatology Progress Notes:</p> <p>Day of Life: 17.</p>	YH-136-AH

DATE	FACILITY/ PROVIDER	MEDICAL EVENTS	BATES REF
		<p>Physical examination: Weight is 3348 grams, up 85 grams. Vital Signs: 37.1, 149, 45, 71/44 with a mean of 50. Head circumference 35.5 cm, length is 54 cm.</p> <p>Metabolic: Objective: Baby fed well today, taking Enfacare every 3 hours, feeding between 80-100 ml/kg/d. Urine output stable at 6.3 ml/kg/h and he has had 4 stools. Assessment: Stable. Plan: Baby is to be discharged home today. A detailed discharge summary will follow. I have touched base with the pediatrician (York Pediatric Medicine) where office appointment which has been set up for Monday, October 5, 2015.</p>	
10/03/YYYY	Provider/Hospital Name	<p>@1349 hours: Discharge Summary:</p> <p>Admission date: 09/17/YYYY</p> <p>Discharge diagnoses:</p> <ol style="list-style-type: none"> 1. A 39-2/7-week appropriate for gestational age male infant. 2. Respiratory distress. 3. Escherichia coli sepsis. 4. Seizure-like activity. 5. Abnormal EEG. 6. Hyponatremia. 7. Metabolic acidosis. 8. Respiratory alkalosis. 9. Hypotension. 10. Failed hearing screen. <p>Hospital course by systems:</p> <p>Respiratory: Baby was transferred from XXXX Hospital on day of life 1 on nasal CPAP due to increasing work of breathing and seizure-like activity. On admission here, due to worsening respiratory status, he was intubated; however, he developed significant respiratory alkalosis and was weaned to ET CPAP by day of life #2. He remained intubated until day of life #7 when he was extubated to room air and remained stable.</p> <p>Metabolic: Due to his clinical presentation, baby was kept nothing by mouth. A UVC and a peripheral arterial line were placed. He received a fluid limit of 60 ml/kg/d. Due to hypovolemia and hypotension, he received normal saline boluses. He also had significant hypoglycemia with blood sugars in the 20s and received D10W boluses. Due to poor response despite fluid boluses, baby was started on Dopamine infusion. He remained on this infusion until day of life #5 when it was discontinued. Arterial blood gas on admission was 7.2/30/40/14/-14.</p>	YH-34-AH- YH-38-AH, YH-79-REF, YH-352-AH- YH-354-AH

DATE	FACILITY/ PROVIDER	MEDICAL EVENTS	BATES REF
		<p>This gradually corrected in response to volume. However, he did develop significant hyponatremia between day of life #1-2 with the lowest sodium level of 121. He received 3% saline correction and increased sodium in TFN and by day of life #3, his sodium level was much improved. A metabolic workup was done and ammonia was slightly increased at 173 on September 17, 2015. This was repeated and ammonia level had decreased to 78 by September 18, 2015. He had an elevated lactic acid of 4.4. Urine organic acids, serum ammonia, CSF amino acid and serum gastrin levels were sent. At the time of discharge, serum amino acids results were available and were abnormal. A repeat specimen was sent on October 3, 2015, and is still pending. Due to his presentation, baby was kept nothing by mouth for 5 days. Small feeds were started on day of life #6 via nasogastric. He achieved full feeds by day of life #8 and was made ad lib by day of life #10.</p> <p>Cardiovascular: Baby suffered from transient hypotension requiring Dopamine infusion. He remained on this infusion until day of life #5. His cardiac enzymes were significantly elevated, but he improved clinically over the course of time.</p> <p>Hematologic: Baby did not receive any blood product transfusion during his stay.</p> <p>Infectious disease: A blood culture was drawn at XXXX Hospital and grew Escherichia coli. Baby was on Ampicillin, Gentamicin and Acyclovir. HSV PCR was sent and was negative by day of life #2, for which the Acyclovir was then discontinued. He remained on Ampicillin and Gentamicin until day of life #5. Repeat blood culture that was sent on day of life #2 remained negative to date. Spinal tap was performed that showed WEC of 13, RBC of 325, glucose of 36, CSF protein of 142 and lactic acid of 8. CSF culture remained negative.</p> <p>Neurologic: Baby was noted to have seizure-like activity at XXXX Hospital and was transferred to our care on day of life #1. He received a loading dose of Phenobarbital. An EEG was done on September 18, 2015, which was significantly abnormal and showed isoelectric tracing with no cortical tracing. Phenobarbital was then discontinued. A repeat EEG was done on September 21, 2015, and September 25, 2015, which remained unchanged with isoelectric tracings. He had a head ultrasound that was done on September 17, 2015, and September 21, 2015, which was within normal limits. A CT scan of the brain was done on day of life #1, which showed significant - diffuse cerebral edema. This was followed by an MRI, which was done on September 21, 2015, which showed diffuse cerebral ischemia changes. Cerebral edema in comparison to CT scan was improving on the MRI. Baby</p>	

DATE	FACILITY/ PROVIDER	MEDICAL EVENTS	BATES REF
		<p>will be followed up with Neurology as an outpatient.</p> <p>Endocrine: MDT was sent on September 17, 2015, which, showed increased 17-OHP. Hershey Endocrine was then contacted and a repeat 17-OHP level was sent and was less than 8 (within normal limits). MDT was then repeated on September 20, 2015, and was normal.</p> <p>Physical examination: General: This is a 39-2/7 week full-term male Infant at day of life 17, who is on room air and pink in an open crib. Vital Signs: Temperature 37.1 axillary, heart rate 149, respiratory rate 45, blood pressure 71/44 with a mean of 51. Discharge weight 3348 grams, head circumference 35.5 cm, length 54 cm. Skin: Pink, warm and dry. The infant does have a Mongolian spot just above the buttocks. There are no other rashes or lesions observed. HEENT: The infant is normocephalic; however, there is noted to be a bony protrusion in the occipital area. The anterior and posterior fontanelles are soft and flat. Ears are symmetrical. The pupils are round and reactive to light and there is a positive red reflex; however, the right pupil is slightly larger than the left, which is not a new finding. Gastrointestinal: Soft and nondistended. There are positive bowel sounds in all 4 quadrants and the infant's umbilicus is clean and dry. Genitourinary: There are normal male term testes and the infant is circumcised, which is healing well and the infant is voiding. Extremities: There are no deformities of the hands, feet or spine. Hips: No subluxation. Neurologic: The tone is increased. The infant moves all of his extremities; however, he does have very jerking movements and mild tremors. The infant has positive corneal reflexes, positive gag reflex and a positive Moro reflex. Deep tendon reflexes are intact.</p> <p>Discharge feedings and medications: 1. Enfacare ad lib. 2. No medications.</p> <p>Appointments and referrals: 1. York Pediatric Medicine in 2-3 days. 2. Early Intervention referral. 3. Neurology followup on October 22, 2015. 4. CYS referral. 5. Home nursing visits. 6. Audiology referral in 1 week.</p> <p>Discharge disposition: Baby was discharged home with his mother and maternal grandmother. They verbalize understanding of the instructions that were given. They were reminded of all the followup appointments that he had and agreed to comply with them. A home nursing visit was</p>	

DATE	FACILITY/ PROVIDER	MEDICAL EVENTS	BATES REF
09/17/YYYY - 10/03/YYYY	Provider/Hospital Name	<p>arranged.</p> <p>Other related records:</p> <p><i>Assessment</i> (Bates Ref: YH-29-AH, YH-358-AH, YH-361-AH, YH-355-AH)</p> <p><i>Case Management Progress Notes</i> (Bates Ref: YH-161-AH- YH-176-AH)</p> <p><i>Checklist/Verification List</i> (Bates Ref: YH-346-AH- YH-347-AH)</p> <p><i>EKG</i> (Bates Ref: YH-650-AH- YH-651-AH)</p> <p><i>Flow Sheet</i> (Bates Ref: YH-238-AH)</p> <p><i>Input / Output Record</i> (Bates Ref: YH-359-AH- YH-360-AH)</p> <p><i>Medication Sheets</i> (Bates Ref: YH-447-AH- YH-456-AH, YH-78-AH- YH-92-AH)</p> <p><i>Orders</i> (Bates Ref: YH-39-AH- YH-49-AH, YH-77-AH, YH-93-AH- YH-124-AH)</p> <p><i>Plan of Care</i> (Bates Ref: YH-155-AH- YH-160-AH)</p> <p><i>Nursing Flow Sheet</i> (Bates Ref: YH-223-AH- YH-224-AH, YH-227-AH- YH-237-AH , YH-239-AH- YH-339-AH)</p> <p><i>Orders</i> (Bates Ref: YH-49-AH- YH-76-AH)</p> <p><i>Nursing Notes</i> (Bates Ref: YH-181-AH- YH-199-AH, YH-201-AH- YH-217-AH)</p>	
10/05/YYYY	Provider/Hospital Name	<p>Follow-up Visit:</p> <p>Subjective: NICU follow up.</p> <p>History: Patient is former 3165 gm infant been at 39 WGA after pregnancy complicated by preterm labor, maternal fever.</p> <p>Chief Complaint: Late 1 week WCC/NICU follow up Formula- Enfamil newborn Birth weight: 7 lbs 0 oz Today: 7 lbs 9 oz.</p> <p>Assessment: Health examination for newborn 8 to 28 days old</p>	YP-12-REF- YP-14-REF

DATE	FACILITY/ PROVIDER	MEDICAL EVENTS	BATES REF
		<p>History of Sepsis in newborn Abnormal EEG Failed newborn hearing screen</p> <p>Orders: Follow-up 1 month Well Child Check Follow-up 1 week weight check Specialty follow-up/referrals: Early Intervention Services: ___ given to parent Pedo Neurology on 10/22/15 at 0845. Audiology to contact with appointment. Out-patient speech, neurodevelopmental clinic and family and child ___ referrals made by NICU.</p>	
10/06/YYYY	Provider/Hospital Name	<p>Referral report: Referral Peds feeding (OT/Speech) evaluation and treat</p> <p>Duration-Frequency: Per clinical discretion</p>	WPR-54-AH, WPR-36-AH- WPR-40-AH
10/07/YYYY	Provider/Hospital Name	<p>Speech Therapy/Feeding Evaluation Consultation:</p> <p>Treatment diagnosis: Oral dysphagia.</p> <p>Current diet: Parent reports that he is continuing to use the Nuk bottle system with a slow flow nipple. She reports that there is only 1 bottle of these at home; that they have other bottles but they are not using them. They are strictly using the Nuk bottle system. He is consuming Enfacre 22 calories and he is offered 4 ounces in which he will drink in approximately 15-20 minutes every 2-3 hours per parent report. At his visit today, he had last eaten at 6:00 and the appointment scheduled this morning was at 11:00. Parent reports that his appetite is good. Grandmother and Great-grandmother both reporting that the patient is beginning to cry to indicate hunger.</p> <p>Oral Motor Assessment: Facial symmetry noted. Oral structures appear healthy and pink. Palate is round and intact. The patient is edentulous, which is age appropriate. The patient was able to establish a strong nonnutritive suck with adequate tongue cupping and intraoral pressure. He was offered a Nuke slow flow nipple for a nutritive suck. He was able to begin with adequate tongue cupping and strong intraoral pressure for suction for adequate milk transfer; however, as the feeding continued the suction and Intraoral pressure significantly decreased and the bottle was easily able to be removed from his oral cavity with active sucking. This is something that is significantly from when he was last seen in the NICU by this speech therapist, which is approximately 1 week ago. The patient is overall demonstrating decreased lingual cupping and intraoral pressure establishment that is needed for adequate oral</p>	YP-20-REF- YP-24-REF, WPR-31-AH- WPR-32-AH

DATE	FACILITY/ PROVIDER	MEDICAL EVENTS	BATES REF
		<p>feeding. The patient was ultimately able to consume 3 ounces in 16 minutes during today's evaluation. The patient is presenting at this time with a mild oral dysphagia that may begin to negatively impact his oral intake and volume intake and his overall efficiency for adequate milk transfer. If the nutritive suck and tongue cupping continues to decrease-and diminish, he may benefit from a compression-only system.</p> <p>Clinical Assessment: The patient is presenting with a mild oral dysphagia which is characterized by diminishing lingual cupping with nutritive Suck on a Nuk orthodontic nipple. If lingual cupping and milk transfer continue to decrease, the patient may benefit from compression-only bottle system for adequate oral intake and efficiency of oral intake. Results of the evaluation were discussed with both mom and family members that were present during the time of the evaluation.</p> <p>Today mom did little talking and great-grandmother did the majority of the talking during the evaluation today. She did indicate that she feels that he is doing perfectly fine with his feeding and truly is denying any concerns with his oral feeding. Home recommendations were provided both in written and in verbal form, the patient would benefit from follow up with 4 speech language pathologist to determine overall suction skills with oral intake. It is likely that if the tongue cupping continues to decrease, that patient would benefit from a compression-only system. Therefore, the speech therapist is recommending to follow up with the family and patient in approximately 2 weeks. Parent is in agreement with the plan of care. An appointment card was provided to mom with the appointment of October 22, 2015, at 11:00 am. It was also recommended that mom begin to keep a detailed feeding log that consists of the start time, end time, and amount that he consumed for each feeding so that way we can determine a true pattern of his overall feeding schedule at this time. It is recommended he continue with the Nuk bottle with a slow flow nipple. It is recommended that he be offered 3-4 ounces. If he consumes 3 ounces that is adequate for growth per the discharge doctor. Education was also provided regarding not wanting to over feed him for the likelihood that he may spit up.</p> <p>Plan: The patient is to be seen 6 times within a 12-week period with a speech therapist to address his oral motor deficits and to determine an adequate feeding plan that will meet his oral needs and his nutritional needs.</p>	
10/22/YYYY	Provider/Hospital Name	<p>ER Record for runny nose:</p> <p>Chief complaint: Mother states that patient has had runny nose since yesterday.</p>	MH-150-AH- MH-154-AH, MH-248-AH, MH-155-AH- MH-175-AH

DATE	FACILITY/ PROVIDER	MEDICAL EVENTS	BATES REF
		<p>History of present illness: The patient is a 5-week-old male presenting to the emergency department with nasal congestion. The mother and grandmother states that the nasal congested started this morning. The child has been increasingly fussy. Still eating and drinking well. Child is formula fed. Still making wet and soiled diapers. No fevers. No coughing. Patient was full-term at birth. The mother states that he did have a short stay in the NICU. They cannot remember why he was in the NICU. No complications since being home.</p> <p>5-week-old infant, vaginal delivery at due time. Has been well until the last 24 hours when he started having runny nose. Family says it is a clear runny nose but he is fussy, is not taking his bottles well. There is no vomiting, he is not coughing. There are no fevers.</p> <p>Evaluation: This is a healthy appearing 5-week-old. TMs are clear nose has obvious nasal secretions bilaterally. Throat is clear moist mucous membranes. Lungs are clear bilaterally heart regular rate and rhythm abdomen is soft. Genitalia within normal limits.</p> <p>I explained to the parents including the nose clear was important and the baby would not be able to feed or breathe normally with secretions in his nose.</p> <p>However use a bulb syringe and showed the parents how to use saline to suction the nose. Baby is to be rechecked by pediatrician tomorrow.</p>	
10/22/YYYY	Provider/Hospital Name	<p>Neurology Follow-up Visit:</p> <p>Chief Complaint: Patient is a 1 month old male with complaints of prematurity, seen in the NICU by Dr. Khera.</p> <p>History of present illness: Patient is here for a neurodevelopmental followup. He is accompanied by his mother and maternal grandmother and they provide his history.</p> <p>The patient's Apgars at delivery were 2 at one minute and 7 at five minutes. Cord gas was 7.19. The patient was admitted to XXXX Hospital's NICU for 17 days and discharged to home on October 3, 2015.</p> <p>During his Neonatal Intensive Care stay, MRI imaging was performed which revealed global cerebral edema and ischemic changes. Initially, the infant was having seizures and placed on phenobarbital, but this was discontinued prior to his discharge as seizures resolved. EEG findings were abnormal. Mother reports that since he has been discharged to home, he has had no abnormal motor movements or acute seizures that they have witnessed.</p>	WPN-20-AH- WPN-23-AH

DATE	FACILITY/ PROVIDER	MEDICAL EVENTS	BATES REF
		<p>They report that patient is currently taking Enfamil approximately 4 ounces every 2-3 hours around the clock. They do have to wake him as mother states "all he does is want to sleep." He is gaining weight. Mother reports he wets diapers with every feeding and has several soft stools a day.</p> <p>Mother reports that he is moving arms and legs equally and she does not notice any stiffening or spasticity. Mother feels when patient opens his eyes, he does try to look at them, however, he is not yet tracking them or any objects.</p> <p>Mother is aware that patient did fail his hearing screening and she is not sure if he is able to hear anything. She does feel that he startles to loud noises at home, but this is not consistent.</p> <p>Patient is followed by Katie Hein-Schultz, MS CCC-SLP, and the Feeding Team on an outpatient basis and does have a followup appointment there later today. Early Intervention is seeing him weekly at their home.</p> <p>Physical Exam: General examination: The patient was sleeping and in no distress. He awoke briefly during examination. Anterior fontanelle is soft and flat There is some overriding of the occipital bones. Red reflex is present. Funduscopic examination revealed sharp, optic disks. Heart was regular rate and rhythm without murmur. Lungs were clear to auscultation bilaterally. Abdomen was soft, nontender nondistended with no masses or organomegaly. There was no scoliosis or sacral dimple. Normal genitalia is present. Mongolian spots were noted on upper back and sacral spine.</p> <p>Neurologic examination: Pupils are equal, round and reactive to light. Extraocular movements were intact. Visual fields and acuity could not be assessed. He did not regard face or track. Face is symmetric and intact. Tongue was midline and palate elevation was equal. Strength is antigravity and symmetric in upper and lower extremities. Muscle tone was normal. There was no abnormal posturing on vertical or ventral suspension.</p> <p>Deep tendon reflexes were 2+ and symmetric in upper and lower extremities. Moro reflexes was intact. Palmar and plantar reflexes were absent. Head lag was present on traction. The patient was unable to hold his head up when placed in a prone position.</p> <p>Plantar response is up going bilaterally. Sensory examination was intact light touch. There was no tremor or titubation noted.</p>	

DATE	FACILITY/ PROVIDER	MEDICAL EVENTS	BATES REF
		<p>Assessment: Failed newborn hearing screen. Sepsis in newborn. Abnormal EEG. Abnormal finding on MRI of brain; diffuse cerebral ischemic changes.</p> <p>Orders: 1. Continue with Early Intervention services. 2. Continue follow up with feeding team/Katie. 3. Please keep his audiology appt. with Hershey medical center next month. 4. I want to see patient back in December for follow up. Please call me in the interim with any questions or concerns.</p>	
10/22/YYYY	Provider/Hospital Name	<p>Speech Therapy Follow up visit: (Illegible Notes)</p> <p>Recommendations: Continue with Nuk bottle and slow flow nipple Only feed him newborn formula Keep feeding log with start time, end time and how much he took Continue to burp frequently (approx. every 1 oz) to avoid gassiness. Next appointment 11/09 at 11 AM.</p>	WPR-55-AH- WPR-56-AH
11/10/YYYY	Provider/Hospital Name	<p>ER Record:</p> <p>Chief Complaint: Patient with grandmother, reports not eating well, vomiting when eating. Failed hearing exam, concerned because he cries often.</p> <p>History of present illness: 7-week-old full-term male who is status post 17 days in the Neonatal Intensive Care Unit for neonatal sepsis with feeding issues and diffuse cerebral ischemia on cerebral ischemia on MRI presents today for problems feeding. Per the mother and grandmother, patient used 4 ounces of Enfamil every 2-3 hours but in the last two days he has not even been eating one ounce. He has been increasingly fussy and has not had some associated diarrhea. Patient follows with speech therapy for difficulty with feeding.</p> <p>Medical decision making: 8 week old male with a complicated past medical history who presents as per HPI. Given history, concern for failure to thrive secondary to social vs organic issue, No signs of infection with current examination. We reviewed notes from speech therapy with which patient follows. Concern for difficulties with outpatient follow up. We consulted pediatrics for further management of his care for possible admission. Discussed with Dr. Gonzales.</p> <p>Impression and plan: Failure to thrive Condition: Stable</p>	YH-463-AH- YH-466-AH, YH-460-AH- YH-463-AH, YH-467-AH- YH-473-AH

DATE	FACILITY/ PROVIDER	MEDICAL EVENTS	BATES REF
		<p>Disposition: Patient care transitioned to Cynthia Martin, CRNP</p> <p>Addendum: Patient is afebrile here in the emergency department. He does not appear in any significant distress. He has a strong cry and the child's mother states that his cry is unchanged from birth. He has a soft and flat anterior fontanelle. It is unclear what exactly is causing the child to feed last. Given his complex history and limited previous followup as an outpatient the family has had previously with him, we are most comfortable discussing the case with pediatrics for further input.</p>	
11/10/YYYY	Provider/Hospital Name	<p>Pediatrics History and physical:</p> <p>Chief complaint: Feeding difficulty for 2-3 days and diarrhea for 2 days.</p> <p>History of present illness: The patient is a 56-day-old male who presents to XXXX Hospital for concern of difficulty feeding by the patients mother and grandmother. They report for the past 2-3 days instead of taking 4 ounces of Enfamil every 2-3 hours as normal, the patient has only been taking 1 ounce. Mom describes that there is some loss or formula after this 1 ounce is given. The patient does spit some of it up out of the corner of his mouth, not in a projectile fashion. His feeds typically last between 30-40 minutes.</p> <p><i>History reviewed</i></p> <p>The patient is seen by XXXX Hospital Feeding Team, Katie Heinschultz, MS, CCC-SLP. Ms. Schultz had a goal of continuing the patient with a Nuk bottle with slow-flow nipple with a goal to be seen 6 times over a 12-week period until the patient is able to meet nutritional goals. Birth weight is noted as 3165 grams. Today's weight is 4240 grains. There does appear to be ample weight gain. The patient's mother and grandmother report that there is no concern for infection, no sneezing reported, no tugging of the ears, no bulging fontanelle, no fever recorded at home. However, they do report 2 days of loose stool but normal production of wet diapers, between 7-10 wet diapers per day. Of note, upon arrival on the Pediatric Floor, the patient did produce 1 bowel movement and 1 wet diaper. In the Emergency Department, there was no lab work performed or medications given. The patient does not take medication at home. The patient is seen weekly by Early Intervention and followed by Pediatric Neurology. There is a history of an abnormal EEG during the patient's NICU stay. The patient was briefly treated with phenobarbital but after resolution of seizure activity, this medication was discontinued. Patient also failed newborn hearing screen x2, appointment with Hershey Audiology scheduled for 11/18.</p> <p>I personally fed baby upon arrival to the floor. I was able to</p>	YH-477-AH- YH-482-AH

DATE	FACILITY/ PROVIDER	MEDICAL EVENTS	BATES REF
		<p>successfully get him to take 3.5 oz in about 15 minutes. He tends to take several large hard swallows, then pulls head away, flails his arms, but if Nuk nipple reintroduced will again take several large swallows. It seemed helpful to provide gentle pressure to his chin. There was minimal formula leakage during feeding. I do wonder if mother is misinterpreting body language for not wanting to feed further given this developmentally challenged infant.</p> <p>Assessment and plan: The patient is an 8-week-old male with feeding difficulty of nonorganic origin.</p> <ol style="list-style-type: none"> 1. Fluid, electrolyte and nutrition: We will place the patient on the home regime of infant formula, Enfamil. We will acquire a speech therapy consultation ideally to have the Feeding Team visit the patient here in Pediatric department. Because the patient was able to take 3 ounces over 15 minutes while on the floor, there appears to be an education deficit with need for education on feeding persistence. The patient will tolerate appropriate volume of formula with proper encouragement. 2. Cardiac and respiratory: There is no acute process at this time. 3. Infectious disease; We will acquire CBC, CMP and CRP in order to rule out infectious process. 4. Neurologic: There is no acute process. <p>Disposition: Once Case Management and Speech Therapy have weighed in, the patient continues to tolerate appropriate amounts of formula during -regular feeding.</p>	
11/11/YYYY	Provider/Hospital Name	<p>Pediatric Progress Notes:</p> <p>Patient seen in room at bedside. No acute events overnight. Patient is resting peacefully.</p> <p>Assessment and plan:</p> <ol style="list-style-type: none"> 1. Fluid, electrolyte and nutrition: We will place the patient on the home regime of infant formula, Enfamil. We will acquire a speech therapy consultation ideally to have the Feeding Team visit the patient here in Pediatric department. Because the patient was able to take 3 ounces over 15 minutes while on the floor, there appears to be an education deficit with need for education on feeding persistence. The patient will tolerate appropriate volume of formula with proper encouragement. 3. Infectious disease: We will acquire CBC, CMP and CRF in order to rule out infectious process. 4. Neurologic: There is no acute process. <p>Disposition: Once Case Management and Speech Therapy have weighed in, the patient continues to tolerate appropriate amounts of formula during regular feeding.</p>	YH-500-AH- YH-502-AH

DATE	FACILITY/ PROVIDER	MEDICAL EVENTS	BATES REF
11/11/YYYY	Provider/Hospital Name	<p>MS3 Progress Notes:</p> <p>8 week old male with diarrhea for 2 days and difficulty feeding for 3 days. As per nurse, speech therapy was able to successfully feed him 3.5 oz of formula yesterday and he has only had 2 changed diapers in the last 24 hours. His parents had previously stated that he was only taking about 1 oz with formula loss due to regurgitation. Of note, the patient is being seen by speech therapy for feeding issues and will continue to see them for a total of weeks. He is noted to have mild oral dysphagia with diminished lingual cupping.</p> <p>Physical exam: Abdomen: Soft</p> <p>Assessment and plan: 8 week old male presents with diarrhea for 2 days and difficulty feeding for 3 days. Patient is feeding better with speech therapy and has had 2 bowel movements over the last 24 hours for a total of 78 grams.</p> <p>1. FEN: Patient will receive Enfamil - which he receives at home. Speech therapy will continue to see him and provide their recommendations. Patient was able to feed 3.5 oz of formula with the last speech therapy visit - there may be an educational issue with the parents in feeding the patient. This will be discussed with parents. 2. ID: CBC/CRP/CMP appear normal. No acute infectious disease at this time. 5. Neurological: No acute process at this time. He does have a history of possible diffuse cortical injury as stated by EEG on record and abnormal GT.</p> <p>Disposition: Patient may be discharged once feedings are normal and speech therapy has spoken with parents regarding education.</p>	YH-498-AH- YH-500-AH
11/11/YYYY	Provider/Hospital Name	<p>Speech Therapy Evaluation:</p> <p><i>History reviewed</i></p> <p>Diaper bag present in room. Patient with Nuk slow flow, Nuk medium flow. Avent level 1, and generic bottles all in bag. Patient supine in bed upon arrival. Patient drowsy and required significant stimulation to accept pacifier. Patient able to establish suck on pacifier. Decreased lingual cupping noted. Offered Enfamil via home bottle, Nuk slow flow. Anterior loss noted throughout with gulping at times. Patient consumed formula via intermittent suck swallow breathe pattern. 60ccs consumed in 6 minutes. Patient then drowsy with no further attempts at sucking, so per oral discontinued. For this reason, unable to trial other nipples.</p> <p>Question whether anterior loss noted secondary to drowsy state,</p>	YH-566-AH- YH-568-AH

DATE	FACILITY/ PROVIDER	MEDICAL EVENTS	BATES REF
		<p>patient not feeling well given diarrhea PTA, or whether secondary to improved suck with increased ability to draw milk from nipple. RN reported that patient did well with hospital slow flow overnight, taking 3.5 ounces. Recommend to trial hospital slow flow at this time with plan to determine appropriate home bottle. SLP spoke with RN, Dawn, re: feed and plan. Feeding plan hung on crib. SLP to attempt to follow up this PM to discuss with RNs.</p> <p>Assessment: Oral dysphagia, feeding difficulty</p> <p>Plan of care: Frequency: 4 times/week for 2 weeks</p>	
11/11/YYYY	Provider/Hospital Name	<p>Ultrasound:</p> <p>Indication: Prematurity</p> <p>Impression: Periventricular leukomalacia likely due to early ischemic change, infection can sometimes have a similar appearance and therefore correlation with clinical findings is necessary. Follow up by MR may be considered.</p>	YH-561-AH- YH-562-AH
11/11/YYYY	Provider/Hospital Name	<p>Lab report:</p> <p>Low: BUN 5, creatinine <0.20, CO2 20, hemoglobin 11.4, hematocrit 31.8</p>	YH-563-AH- YH-564-AH
11/12/YYYY	Provider/Hospital Name	<p>MS3 Progress Notes:</p> <p>This morning, at 0400, patient was able to retain 100 ml of formula given by the nurse. Of note, the patient is being seen by speech therapy for feeding issues and will continue to see them for a total of 12 weeks. He is noted to have mild oral dysphagia with diminished lingual cupping. Also, head anomaly was discovered yesterday on physical exam, and we obtained an ultrasound. Ultrasound results came back with periventricular leukomalacia, most likely due to early ischemia or infection. Patient had 3 diaper changes yesterday.</p> <p>Physical exam: HEENT: Apparent subluxation of left temporal bone beneath the occipital bone.</p> <p>Assessment and plan: 1. FEN: Patient will receive Enfamil - which he receives at home. Speech therapy will continue to see him and provide their recommendations. Patient was able to feed 100 ml of formula with the nurse last night. Speech therapy recommending a trial plan with slow flow to determine the right nipple for feedings. 2. Periventricular leukomalacia - Possible MRI to follow-up ultrasound results. He does have a history of possible diffuse cortical injury as</p>	YH-497-AH- YH-498-AH

DATE	FACILITY/ PROVIDER	MEDICAL EVENTS	BATES REF
11/12/YYYY	Provider/Hospital Name	<p>stated by EEG on record and abnormal CT.</p> <p>Pediatric Progress Notes:</p> <p>Continues to do well, feeding without difficulty. No acute events.</p> <p>Assessment and plan: <i>Remains the same as that of previous day</i></p> <p>Assessment and plan: Baby now feeding well, taking approx. 3-4 ounces with each feed. Feeding team/speech involved, will continue to follow patient as an outpatient Will arrange for home nurse visits. Baby stable for discharge home.</p> <p>Disposition: Discharge home with home nursing visits. Follow up Pediatrician in outpatient.</p>	YH-494-AH- YH-497-AH
11/12/YYYY	Provider/Hospital Name	<p>Discharge Summary:</p> <p>Date of admission: 11/10/15.</p> <p>Hospital Course: 8-week-old male initially presented for difficulty feeding brought in by mother and grandmother. This was found to be mainly in education deficit, and retraining of feeding. While hospitalized patient has been feeding without difficulty he does require some redirection. Speech and swallow were consulted and had no concerns for discharge. Case management was also involved. On examination the only thing to note were some overriding sutures, he has been followed by neurology since birth. He has had a CT and an MRI in the past. We repeated an ultrasound of his head which demonstrated periventricular leukomalacia. Otherwise had no issues. Home nurse visits scheduled. Will have them follow up in outpatient.</p> <p>Disposition: Home or family.</p> <p>Diagnosis: Feeding problem in infant.</p> <p>Diet: Other: Enfamil formula 3-4 ounces every 3-4 hours.</p> <p>Follow up: Family first health-york- 5 to7 days. Home nurse visit on 11/13/YYYY.</p>	YH-485-AH- YH-486-AH, YH-483-AH- YH-485-AH, YH-507-AH- YH-542-AH, YH-565-AH, YH-568-AH- YH-571-AH, YH-545-AH- YH-560-AH, YH-503-AH- YH-506-AH
12/01/YYYY	Provider/Hospital Name	<p>Speech Therapy Discharge summary:</p> <p>Date of onset: 10/07/YYYY</p> <p>Clinical Assessment: The patient continues to present with a mild oral dysphagia which is characterized by diminished lingual cupping with a</p>	WPR-44-AH- WPR-46-AH, WPR-57-AH

DATE	FACILITY/ PROVIDER	MEDICAL EVENTS	BATES REF
		<p>nutritive suck. The patient is able to establish an adequate suck on a Nuk nipple to allow for milk transfer in a timely fashion. However, at his last appointment on October 22, 2015, the patient arrived 60 minutes late.</p> <p>The patient did not bring a bottle nor did she bring formula. A bottle and formula was retrieved from the NICU at that time. He was offered 4 ounces via a Nuk nipple that was provided by the speech therapist. He was observed to consume 2-1/2 ounces in approximately 12 minutes. The patient's naked weight at the appointment on October 22, 2015, was 9 pounds 1-1/2 ounces, which was up from his weight on the date of the evaluation of October 7, 2015, which was 7 pounds 9-112 ounces so weight gain was present. The patient's overall nonnutritive suck on a gloved finger was established. He was about 50% independent with suction on a pacifier without anterior loss. It was recommended that he continue with a Nuk nipple secondary to the overall difficulty with his lingual cupping at that time. Education was provided at the time of this evaluation and treatment session regarding the importance of keeping a feeding log which was not brought to the appointment on October 22, 2015. The parent agreed to start one that day and maintain in order to determine how much formula he was consuming in each day and how long each formula feeding was taking.</p> <p>Overall patient does continue to exhibit a mild oral dysphagia that is characterized by diminishing lingual cupping. The patient continues to benefit from the use of an orthodontic nipple which is slow flow. The parents are reporting that they are continuing to use this at home; however, during the discharge conversation on December 1, 2015, the parent did report that he was consuming 4 ounces. The length of time in which he was taking to consume that was not disclosed but the parent did report that he has been doing well, reported that he has been gaining weight although he had not had a followup appointment with the doctor at that time. The parent agreed to reach out to the speech language pathologist if feeding difficulties occur in the future; however, at this time, he is being discharged secondary to not being able to attend appointments in a timely fashion and the need to cancel and reschedule frequently.</p> <p>Plan: The patient is to be discharged from Speech Therapy Feeding Services secondary to difficulty attending appointments in a timely fashion and overall increase of cancels and no shows. If feeding services are recommended in the future, it is recommended that the family acquire a new script in order to be seen by the Feeding Clinic. The parents were provided with my contact information, specifically, the telephone number, as far as how to reach the speech therapist if needed.</p>	
12/14/YYYY	Provider/Hospital Name	<p>History and Physical:</p> <p>Chief complaint:</p>	YH-572-AH- YH-576-AH, YH-584-AH-

DATE	FACILITY/ PROVIDER	MEDICAL EVENTS	BATES REF
		<p>Failure to thrive and to rule out seizures.</p> <p>History Of Present Illness: This is a 2-month old male, with a significant birth history.</p> <p><i>History reviewed</i></p> <p>He has a longstanding history of failure to thrive. He was last hospitalized November again, with difficulty in feeding and diarrhea. In speaking with his mother, grandmother and aunt, baby feeds at least every 2-3 hours consuming at least 4 ounces. His formula is made with 2 scoops of Enfamil Newborn for 4 ounces of formula. After feeds, he does tend to throw up a very little bit. His emesis is nonbloody, nonbilious. Mother describes it as a minimal amount of formula. Emesis is never projectile. It should be noted that the mother does describe him as a messy eater. She also notes that it takes him about 30-40 minutes to finish a bottle and he does typically burp a lot after feeds. Looking at his past charts, his weight on November 10, 2015, he was 4.24 kilograms. Today he is 4.53 kilograms/ that equals about 8.5 grams a day, which is below 20-30 mg designating him a failure to thrive, prior to this he was gaining weight appropriately.</p> <p>Furthermore, mother notes that the baby has been demonstrating some posturing over the last 2-3 weeks. She describes it as an extension of the arms and flexion of the elbows with hands at the head and flexion of the hips and knees. These episodes tend to last for 1-2 minutes. It happens about once or twice a week. Mother cannot pinpoint any specific things that trigger this behavior. After the posturing ends, the baby tends to go back to being normal with no signs of lethargy nor any other abnormalities. Mother denies any recent fever, lethargy, diarrhea reduction in wet or dirty diapers or change in overall state.</p> <p>Physical examination: HEENT: His head has what appears to be an indent in the left inferior occiput. He does have overriding of the sagittal suture on the right. His head is microcephalic. Neurologic: He is moving all extremities independently. He demonstrates a head lay with lifting, still evidence of the Moro reflex.</p> <p>Assessment And Plan: This is a 2 month old male with severe cerebral insult with mild herniation of the brain and hypoxia post birth, with failure to thrive and questionable seizure activity.</p> <p>Fluids, Electrolytes And Nutrition: Encouraged family to use home Enfamil for newborn and home bottle to assess how baby actually feeds at home. As of this point, no intravenous hydration is necessary.</p> <p>Neurologic: There is a concern for possible seizures therefore, we will</p>	YH-585-AH

DATE	FACILITY/ PROVIDER	MEDICAL EVENTS	BATES REF
		<p>order a bedside, EEG which will be interpreted by Pediatric Neurology; they will also consulted.</p> <p>Gastrointestinal: As mentioned above the patient will be kept on home Enfamil and home bottle feeds to more closely monitor how the baby feeds at home. Furthermore, the baby does have a relatively obvious tongue-tie. We will have Speech evaluate the need surgical correction of Tongue Tie, as well to evaluate feeding. We will also order complete metabolic panel to evaluate for malnutrition or any other abnormalities.</p> <p>Hematologic: Evaluate a CBC as the patient was previously mildly anemic on laboratories.</p> <p>Social: The plan has been discussed with mother, grandmother and aunt, they agree with the plan and are on board. It should be also noted that this child been previously, evaluated by Children and Youth Services. We will consult Case Management for their stay. We will continue to monitor.</p> <p>Disposition: Long term prognosis for this child is very poor. We will continue to monitor patient overnight, make sure there is adequate oral intake. We will also follow the recommendations of Speech and Feeding as well as Neurology. This patient will be here for a minimum of 2 midnights.</p>	
12/14/YYYY	Provider/Hospital Name	<p>@1243 hours: Neurology Consultation:</p> <p>Chief Complaint: Patient is a 2 month old male returning for follow-up for neonatal sepsis complicated by seizures and respiratory difficulties.</p> <p>History of present illness: Patient is here for neurodevelopmental follow-up. He is accompanied to today's appointment by his mother and her mother, and together they provide his interim history. He was last seen in my office October 22, 2015, and at that point in time recommendations were that he continue with Early Intervention Services, which he has been receiving follow-up with Family Child Resources for parenting support, continue without patient speech and feeding team appointments, which mother did not keep. Pediatric Audiology consultation at Hershey Medical Center, which was completed and his hearing is normal, and his regularly scheduled Pediatric appointments, which mother has not followed up with.</p> <p>Mother reports that patient continues to take Enfamil formula and he takes anywhere from 4-8 ounces every 3-4 hours. It takes him approximately 30 minutes to finish a bottle. Mother reports that he will spit-up and/or vomit typically with each feeding anywhere from a small to a large amount. They report that he has multiple wet diapers</p>	WPN-24-AH- WPN-28-AH

DATE	FACILITY/ PROVIDER	MEDICAL EVENTS	BATES REF
		<p>per day at least 8-10, and has 3-4 stools per day.</p> <p>Mother feels that he is starting to turn his head to her face and her voice. He is not yet cooing or smiling. He tends to be a more irritable baby and often cries for long periods throughout the day. Mother states she does place him on his back to sleep.</p> <p>With regard to seizure activity, mother denies seeing any abnormal motor movements; however, she states that at times it appears that patient is "trying to sit himself up." Upon further discussion, she states that he will be lying down on the bed and suddenly jerk up forward like he is trying to sit up. She noticed this last week and is unsure how often it happens. Mother and grandmother are not good historians. An Early Intervention supervisor, Heather, is present at today's visit to assist the family and coordinate services.</p> <p>Mother reports that patient's head is oddly shaped and very flat on one side. She states someone told her to put a towel behind his head on that side to keep his head in a certain position.</p> <p>When asked why patient has not had his followup appointments as recommended, mother states she was going to change pediatricians and could not explain why she did not follow up with feeding as recommended. It appears that mother was unaware of when she had certain appointments and she was unclear of which appointment patient had to attend.</p> <p>When asked if mother's Children and Youth case worker was still involved, mother reported, "No." Early Intervention supervisor reports that their Children & Youth Services case is still open and they do have a specific caseworker. She will touch base with them later on today.</p> <p>When discussing patient's lack of weight gain with his mother and grandmother, they speared unaware that he has not gained any weight in the past 2 months.</p> <p>There is also concern for craniosynostosis due to his abnormal head shape and lack of head growth. His mother and grandmother were advised that it is unclear if patient is so irritable due to his lack of growth and poor nutritional status, if there is a brain issue that we are unaware of such as recurrent seizures or craniosynostosis, or if this is put of his outcome due to his neonatal history.</p> <p>Physical Exam: He is awake, irritable and crying the majority of the visit. He is not comforted with a pacifier. Poor latch is noted on the NUK nipple. No vomiting was noted during this appointment. He is fallen off the growth curve and is less than 1st percentile and height weight and</p>	

DATE	FACILITY/ PROVIDER	MEDICAL EVENTS	BATES REF
		<p>head circumference.</p> <p>General examination: Head is microcephalic. Anterior fontanelle is not appreciated on exam. Left occipital flattening is noted with prominent overriding of sutures. Reflexes are symmetric and intact. Fundoscopic examination was unable to be performed during today's appointment. Heart was regular rate and rhythm without murmur. Lungs were clear to auscultation bilaterally. Abdomen was soft non tender nondistended with no masses or organomegaly. There was no scoliosis or sacral dimple. There were no neurocutaneous markers. Mongolian spots are noted on upper tuck and over sacral spine.</p> <p>Neurologic examination: Pupils are equal, round and reactive to light. Extraocular movements were intact. Visual fields and acuity could not be assessed. Face is symmetric and intact. Tongue was midline and palate elevation was equal.</p> <p>Strength is antigravity and symmetric in upper lower extremities. Muscle tone was increased. There was no abnormal posturing on vertical or ventral suspension. He moves all extremities symmetrically and without difficulty. He brings both hands to midline but was not observed bring them to his mouth. No rooting reflex was observed. He was unable to hold his head up when placed in a prone position. He has good head control on traction (likely from involving increased tone).</p> <p>Deep tendon reflexes were 3+ and symmetric in upper and lower extremities. Moro, palmar, and plantar reflexes were intact. Plantar response is up going bilaterally. Sensory examination was intact to light touch. Gait was not applicable.</p> <p>Assessment: Abnormal EEG Abnormal finding on MRI of brain; diffuse cerebral ischemic changes. Failure to thrive in infant. Abnormal motor activity. Irritability</p> <p>Orders: As discussed, I am going to admit him to the hospital for further evaluation of his poor weight gain, feeding issues, vomiting/spitting with feedings, and irritability. You are to travel directly to the pediatric floor now from my office. I would like to see patient back in my office in 1 month for follow up.</p> <p>Active Problems: Failed new born hearing screen</p>	

DATE	FACILITY/ PROVIDER	MEDICAL EVENTS	BATES REF
		Consult with HMC audiology - passed hearing exam. 11/15. Follow-up as needed.	
12/14/YYYY	Provider/Hospital Name	<p>@1700 hours: EEG report:</p> <p>History: A 2-month-old with a history of Escherichia coli sepsis in a newborn associated with respiratory distress and metabolic acidosis. Previous EEGs were abnormal and MR imaging demonstrated heterogeneous signal on diffusion-weighted imaging bilaterally consistent with diffuse heterogeneous cerebral ischemic changes.</p> <p>Impression: This is a markedly abnormal tracing due to the following: 1. Suppression of normal cortical rhythms bilaterally over the central, parietal, temporal and occipital regions. 2. Right frontopolar sharp wave. 3. Poorly organized preserved rhythm over the frontal regions bilaterally. These findings would be consistent with a diffuse encephalopathy consistent with the previously described abnormalities on MR imaging.</p>	YH-85-REF- YH-86-REF
12/14/YYYY	Provider/Hospital Name	<p>@2202 hours: Pediatric Neurology Progress notes:</p> <p>EEG has been dictated by Dr. Barron and results dictated (bilateral frontal spikes with slowing, no seizures). He will be started on Gabapentin for irritability which is suspected to be neurological in nature. Dose to start is approx. 16 mg/kg/day. This can be titrated weekly based on his response, and per case series in the literature, final dose ranges from 15 to 35 mg/kg per day divided 3 or 4 times a day. Dr. Benko will see the patient in the hospital on Dec 15.</p>	YH-612-AH
12/14/YYYY	Provider/Hospital Name	<p>Lab report:</p> <p>Glucose 103 (H), creatinine 0.22 (L), Chloride 110 (H), hematocrit 31.3 (L), platelet 445 (H)</p>	YH-724-AH- YH-725-AH
12/15/YYYY	Provider/Hospital Name	<p>@0734 hours: Progress Notes:</p> <p>Subjective: Yesterday, Neurology evaluated him and found bilateral frontal spikes with slowing on EEG but no seizures and was started on Gabapentin. However, last night an irregular heartbeat was auscultated and was placed on telemetry and EGG showed sinus arrhythmia with PVCs and Gabapentin was held for a brief period. After confirming with the pediatric attending, Gabapentin 25 mg thrice daily was started. Overnight, he was awoken around 3 AM for diaper change and feed but was hard to stimulate during the diaper change and refused to take bottle. At 5:30 AM, he was able to be weighed (4.57 kg) and fed 60 ml without trouble. He continues to be woken up every 2-3 hours for feeds. Since Gabapentin was started last night the patient seems sluggish however the mom and grandmother report that this level of activity is within normal range.</p>	YH-608-AH- YH-612-AH

DATE	FACILITY/ PROVIDER	MEDICAL EVENTS	BATES REF
		<p>Physical examination: HEENT: His head has an indentation in the left inferior occiput. There is a coronal suture on the right that is prominent. Cardiovascular: No murmurs, gallops, clicks or rubs. Irregular rate and rhythm. More irregular last night relative to exam this morning.</p> <p>At 0251 hours: Cardiology read showed: Sinus arrhythmia with a single junctional premature beat.</p> <p>Assessment: Patient with significant global hypoxic injury presents with abnormal movement possible new-onset seizures and chronic FTT.</p> <p>Plan: We will continue to monitor feeds on his home regimen of Enfamil newborn formula with strict I/Os. Speech consult/swallow study in AM Neuro consulted and following with Dr. Benko scheduled to see patient today. Continue Gabapentin 25 mg thrice daily per pediatric neurology recommendations. EEG to evaluate for seizure. Consider social services consult to evaluate home and support system in place for adequate care and feeding of patient.</p>	
12/15/YYYY	Provider/Hospital Name	<p>@0920 hours: Pediatric Neurology Progress Notes:</p> <p>Subjective: Chief complaint: Irritability. Irritability improved since started Gabapentin. EEG, though without seizures, had frontal sharps. Feeding better. CYS and feeding team involved. EKG prelim computerized report questionable for PVC.</p> <p>Medication: Gabapentin 25 mg 0.5 ml per oral thrice daily Sodium chloride flush 0.9% 10 ml syringe 5 ml</p> <p>Assessment and Plan: Course: Improved irritability on Gabapentin. Suggest stay on current dose. If time allows, suggest non contrast 3D reconstructive CT of head for evaluation of craniosynostosis. As outpatient should see an Ophthalmologist.</p>	YH-607-AH- YH-608-AH
12/15/YYYY	Provider/Hospital Name	<p>@1133 hours: CT head without contrast:</p> <p>Indication: Craniosynostosis.</p> <p>Impression:</p>	YH-721-AH, YH-108-REF- YH-109-REF

DATE	FACILITY/ PROVIDER	MEDICAL EVENTS	BATES REF
		Extensive bilateral cerebral atrophy with associated deformity of the calvaria.	
12/15/YYYY	Provider/Hospital Name	<p>@ 1133 hours: CT skull with 3D reconstruction without contrast:</p> <p>Indication: Craniosynostosis.</p> <p>Impression: Overlapping sutures, with some foci of fusion, likely secondary to extensive bilateral cerebral atrophy rather than primary craniosynostosis.</p>	YH-722-AH, YH-110-REF- YH-111-REF
12/15/YYYY	Provider/Hospital Name	<p>@ 1317 hours: Nutritional initial assessment:</p> <p>In to see patient for FTT. Patient admitted for evaluation of seizure like activity. PMH is significant for history of neonatal sepsis; hypoxic brain injury; microcephaly.</p> <p>Diet order: Family to provide own formula and bottles for feeding</p> <p>Over past 24 hours, patient received 280 ml Enfamil newborn, 9.3 oz 187 kcal and 4 gm pro</p> <p>Per discussion with patient's nurse, Lisa, patient has been feeding well with smaller size nipple and seems to have a better latch than the nipple the family has been using. Patient had 4 oz of Enfamil newborn at 8 AM without any problem. Per Lisa, feeding did not take an hour as parent reports it has been taking with home feedings. Patient less agitated with Gabapentin per nurse.</p> <p>Aunt fed patient 6 oz at around 10 AM, even though the recommended volume was only 4 oz.</p> <p>Per EMR patient has been receiving 4 oz every 2 – 3 hours which would equate to 32 – 48 oz per day (640 – 960 kcal/day). This seems unlikely given patient FTT and not meeting anticipated weight gain since last admission.</p> <p>Patient with FTT that seems to be related to feeding techniques/feeding frequency. Patient had admission one month ago with similar problem and was able to gain appropriate amount of weight during that admission. Patient now presenting with mild to moderate protein/calorie malnutrition based on calculated Z scores for weight and length.</p> <p>Height 23 inch Weight 4.57 kg</p> <p>Patient would need -34 oz/day for catch up growth. This could be provided as 4 oz feedings every 3 hours.</p> <p>Additional Nutrition Ther/Inter Comments:</p>	YH-699-AH- YH-701-AH

DATE	FACILITY/ PROVIDER	MEDICAL EVENTS	BATES REF
		<ol style="list-style-type: none"> 1. Encourage feeding 4 oz every 3 hours; with nighttime wake-ups if patient still sleeping. 2. Feeding evaluation with smaller nipple size that seems to allow for better latch. 3. Monitor growth to assist with evaluation of adequacy of feedings. 	
12/15/YYYY	Provider/Hospital Name	<p>@1511 hours: Speech Therapy evaluation:</p> <p>Current feeding: Presumably Avent level 1, though level 1 and 2 nipples are in the room. RN has trailed Avent level 1 nipple and reported patient appeared frustrated with it. She trialed the Enfamil regular flow that the hospital currently has in stock, and his coordination and efficiency with the feed appeared much improved.</p> <p>Patient supine and swaddled in bed upon arrival; last feeding was by Grandma at 12 Noon per RN report, 6 oz consumed. Patient drowsy and required significant stimulation to accept pacifier. Required unswaddling to alert, patient then did establish suck on gloved finger. No pacifier retention observed with Nuk pacifier that was in crib with patient. Decreased lingual cupping noted. Tight lingual frenulum noted.</p> <p>Offered Similac via home bottle (Avent bottle with Avent level 1 nipple). Inconsistent lingual seal and inconsistent milk transfer noted. No anterior loss noted. Intermittent Suck swallow breath sequence noted, with self pacing. He consumed 20 cc in 10 minutes. Nipple collapse noted x2.</p> <p>Next attempted Enfamil regular flow nipple (Hospital supplied nipple) revealed more consistent milk transfer, notably stronger intraoral pressure and increased consistency of lingual seal.</p> <p>Recommend to trial hospital's Enfamil regular flow Nipple at this time with plan to determine appropriate home bottle. SLP spoke with RN, Lisa and patient's MD. Feeding plan hung on crib. SLP completed documentation on floor in attempt to meet caregivers (Patient's Mom and Grand-ma) however they have not yet returned to the unit.</p> <p>SLP Diagnosis with severity: Feeding difficulties characterized by inconsistent oral motor abilities.</p> <p>Plan of care: 3x per week for 2 weeks</p> <p>Rationale for Discharge Recommendation: Will likely need outpatient feeding therapy for continued parent/caregiver education and ongoing revisions to feeding plan.</p>	YH-727-AH- YH-730-AH, YH-635-AH- YH-640-AH
12/16/YYYY	Provider/Hospital Name	<p>@0729 hours: Progress Notes:</p> <p>Subjective: Yesterday he was noted to have decreased irritability which was attributed to beginning Gabapentin. Neurology suggested a</p>	YH-604-AH- YH-607-AH

DATE	FACILITY/ PROVIDER	MEDICAL EVENTS	BATES REF
		<p>non-contrast 3D reconstructive CT which showed that there are overlapping sutures with some fusion due to extensive bilateral cerebral atrophy instead of what was thought to be craniosynostosis. During the day yesterday he had improved feeding with the hospital bottle and nipple and drank 120 ml without any problem. Feeding was retried using the home nipples for his 10 AM feed and he seemed to be frustrated and cry after a few sucks and was restarted on hospital nipple. He was able to take 6 oz for his 1 PM feeding without difficulty. He is also noted to have a fussy irritable cry around 5 PM and he is continued to be bottle fed but this time by his mother who was only able to feed 50 cc and the nurse was able to feed up to 120 cc of Similac ready to feed. Overnight, he continued to be irritable per nursing. He did not have any regurgitations with feeding. He took 4 oz at 11 PM, another 2 oz at 12 AM, and was hard to keep awake but took 4 oz around 3 AM and woke up easily for his 5:00 AM feeding. He had multiple wet stools and diapers. After some concerns about the accuracy of what mother and grandmother were saying regarding feeding schedule the social worker was concerned that the family isn't following through with making outpatient appointments as well as medical recommendations. There is a meeting today with York County Children Youth and Family Services and the rest of the team to discuss discharge planning.</p> <p>Physical exam: HEENT: He has an indented left inferior occiput, overriding sagittal suture, and is micro cephalic. He has no discharge coming from his nares.</p> <p>Differential Diagnosis: 1. Failure to Thrive: Organic : He can be diagnosed with failure to thrive because he has only gained about 8.5 g/d which is far lower than the expected 20 g/d increase in infants of his age. There are a variety of endogenous factors that could lead to this presentation including a variety of inborn errors of metabolism. However, gas and acid reflux are possible for this patient because of his history of "messy feeding" and spitting up shortly after feedings. He doesn't have features that would be concerning for absorption of nutrition difficulties including cystic fibrosis, diarrhea, milk allergy, nor celiac disease as family hasn't complained of his inability to produce wet diapers and he has not had diarrhea.</p> <p>2. Failure to Thrive: Organic: Tongue Tie- He does have a tongue tie that could be partially to blame for his difficulty feeding and "messy intake", Ankyloglossia has implications for his ability to develop an adult swallow and could result in speech difficulty.</p> <p>3. Nonorganic FTT: This is also possible because of caregiver difficulties and would need to include an assessment of finances poverty, environment at home, family structure, substance abuse or</p>	

DATE	FACILITY/ PROVIDER	MEDICAL EVENTS	BATES REF
		<p>addiction history, and other issues family education and psychiatric history as these could play into the infant being inappropriately not fed enough or not being fed appropriately. Based on the nursing notes and social worker's report, this is definitely a concern because the family has been inconsistent with reporting feeding and seem to not understand the seriousness of his condition.</p> <p>Plan: FEN: Continue using formula and home regimen to assess his intake. Neurologic: Due to the concern for seizures, Neurology will see him again this morning to assess. Cardiovascular: Continue monitoring patient on the ECG monitors and telemetry for concerns of arrhythmia Gastrointestinal: Review I/O, assess his blood work for imbalance in electrolytes and nutrition status. Feeding/Speech will come today to assess him for his tongue tie. Hematologic: Elevated platelets but other than this, CBC appears normal.</p> <p>Disposition: He will be evaluated by Neurology, Feeding/Speech and discharged per their recommendation.</p>	
12/16/YYYY	Provider/Hospital Name	<p>@1352 hours: Pediatric Progress Notes:</p> <p>Subjective: Since starting Gabapentin he has had noticeable improvement in his level of irritability which is felt to be related to his neurological status. He underwent a 3D reconstructive CT which showed that there are overlapping sutures with some fusion due to extensive bilateral cerebral atrophy however no craniosynostosis. Yesterday feedings improved when fed with the Enfamil hospital supplied nipple. Family continues to need prompting nursing staff to feed baby every 3 hours.</p> <p>Nursing has been able to feed baby 6 oz within 20-30 minutes, however family continues to have difficulty achieving 6 oz in 1 hour. Case management and CYS are involved due to concerns by medical and nursing staff that family is not responsive to education regarding feeding regimen. During this hospitalization (as with the prior admission) patient has demonstrated ability to gain weight at an appropriate rate when fed with the current feeding regimen of feeding every 3 hours and approx. 6oz per feed. His overall weight gain during so far during this admission has been 8.5 oz, which has exceeded expectation of 20-30 grams per day.</p> <p>Physical examination: General: Awake, mom attempting to feed HEENT: Overriding sagittal suture, microcephaly. PERRL. Neurologic: Increased tone throughout, minimal head lag, posturing related to increased tone. Skin: Appears intact this morning yesterday was noted to have a</p>	YH-601-AH- YH-604-AH

DATE	FACILITY/ PROVIDER	MEDICAL EVENTS	BATES REF
		<p>Mongolian spot on the buttocks; otherwise, no lesions or bruises.</p> <p>Plan: FEN/GI: Continue current feeding regimen of 6 oz every 3 hours. Neurologic: Neurology has no further inpatient recommendations. He will continue to need close outpatient follow up. Hematologic: Elevated Platelets but other than this, CBC appears normal.</p> <p>Disposition: To be determined once CYS disposition determined however I am concerned that if patient is returned to the current home he will have recurrence of poor weight gain and failure to thrive.</p>	
12/17/YYYY	Provider/Hospital Name	<p>@0651 hours: Progress Notes:</p> <p>Subjective: Patient seen and examined this AM, sleeping on back in crib. Per nursing, infant slept well throughout shift and needed to be stimulated to feed overnight. Patient seen by SLP yesterday and extensive education regarding feeding given to family. Per case management meeting yesterday, YCCYF will be seeking foster care for the patient who will remain in hospital to ensure steady weight gain.</p> <p>Physical exam: Neurologic: He was moving his extremities when he was asleep-has grasp reflex intact.</p> <p>Plan: FEN: Continue using formula and home regimen to assess his intake. Neurologic: Neurology previously consulted, will continue outpatient follow up. Cardiovascular: Continue monitoring patient on the ECG monitors and telemetry for concerns of arrhythmia Gastrointestinal: Review I/O, assess his blood work for imbalance in electrolytes and nutrition status. Feeding/Speech will come today to assess him for his tongue tie. Hematologic: Elevated Platelets but other than this, CBC appears normal.</p> <p>Disposition: Continue in hospital care to ensure weight gain.</p>	YH-598-AH- YH-601-AH
12/17/YYYY	Provider/Hospital Name	<p>@1026 hours: Pediatric Neurology Progress Notes:</p> <p>Patient has been feeding well and is much calmer now. Grandmother at bedside and reports her main concern is his brain development.</p> <p>Physical examination: General: GM holding patient on her chest. He is awake, whimpers a little, but easily consolable with pacifier and verbal comforting and patting his back. Sutures overriding with left plagiocephaly. Motor: When supine, moves arms and legs antigavity, has good head</p>	YH-596-AH- YH-598-AH

DATE	FACILITY/ PROVIDER	MEDICAL EVENTS	BATES REF
		<p>control on traction and horizontal suspension. Lifts head when prone and against GM's chest.</p> <p>DTR: Brisk at 3+ in arms and legs, no clonus. Has palmar and plantar grasps.</p> <p>No movements concerning for seizures.</p> <p>Medications: Gabapentin 25 mg thrice daily Sodium chloride flush 0.9% 10 ml syringe 5 ml</p> <p>Plan:</p> <ol style="list-style-type: none"> Disposition per GYS discretion. Patient at very high risk for difficulties with weight gain due to irritability and possibly not waking on his own to feed ad lib and other psychosocial limitations. Follow up as an outpatient with neurology -I did review with GM that we may work on getting a helmet for him to help with head shape. I told her it is like this as his head is not growing correctly to keep the bones in the right place. Helmet may help with reshaping only. Continue with same dose of Gabapentin and services through EI and feeding clinic. 	
12/18/YYYY	Provider/Hospital Name	<p>@0656 hours: Pediatric Progress Notes:</p> <p>Subjective: Overnight: No acute events. Reviewed nursing note regarding feeds with grandmother. Patient was seen and examined in his crib this morning. He has been feeding well and gaining weight. He is ok for discharge however is awaiting placement through CYS.</p> <p>Physical exam: Neuro: Good muscle tone; good grasp x 4</p> <p>Medications: Gabapentin (Neurontin) PED POD 25 mg Sodium chloride flush 0.9 10ml syringe 5 ml</p> <p>Assessment: 2 month old male infant that presents with poor weight gain of 8.5 g/day and questionable seizure activity with likely failure to thrive.</p> <p>Plan: Respiratory: ID, Hematology. Cardiac; no concerns at this time.</p> <p>Neurology: Reviewed EEG and 3-D Head CT. There is no seizure activity at this time and no craniosyntosis. However, he will need to follow with outpatient Neurosurgery for overriding sutures. Irritability: Continue Gabapentin at this time.</p> <p>Fluids, electrolytes, GI, Endocrine:</p>	YH-594-AH- YH-596-AH

DATE	FACILITY/ PROVIDER	MEDICAL EVENTS	BATES REF
		<p>Diet: Similac Advance 6 oz every 3 hours. Use nipple from Enfamil newborn bottles for feeding.</p> <p>Failure to thrive: Gained 120g today and taking 0.129kcal/g. He is adequately feeding and gaining weight.</p> <p>Disposition: Reviewed case management note. Patient is being discharge to CYS. He is ok to discharge pending placement in a foster home.</p> <p>Addendum: Discussed with nursing and SW. Patient feeding well and gaining weight (+120 g from yesterday). GM has been bedside, involved in his care, with guidance/encouragement from nurses. Fussy during exam. Misshapen head with prominent overriding sutures and left-sided plagiocephaly.</p>	
12/19/YYYY	Provider/Hospital Name	<p>Discharge Summary:</p> <p>Date of admission: 12/14/YYYY</p> <p>Hospital Course: This is a 2-month-old male, with a significant birth history. He was full-term upon birth, though he was placed in the Neonatal Intensive Care Unit for sepsis and respiratory distress. Upon discharge, he was diagnosed with global hypoxic event and low-grade herniation of the brain. His evaluation for any metabolic abnormality was negative at that time. He did have some mild acidosis during his stay in the NICU as well.</p> <p>He has a longstanding history of failure to thrive. He was last hospitalized November 11, 2015, again, with difficulty in feeding and diarrhea. In speaking with his mother, grandmother and aunt, baby feeds at least every 2-3 hours consuming at least 4 ounces. His formula is made with 2 scoops of Enfamil Newborn for 4 ounces of formula. After feeds, he does tend to throw up a very little bit. His emesis is non-bloody, non-bilious. Mother describes it as a minimal amount of formula. Emesis is never projectile. It should be noted that the mother does describe him as a messy eater. She also notes that it takes him about 30-40 minutes to finish a bottle and he does typically burp a lot after feeds.</p> <p>Furthermore, mother notes that the baby has been demonstrating some posturing over the last 2-3 weeks. She describes it as an extension of the arms and flexion of the elbows with hands at the head and flexion of the hips and knees. These episodes tend to last for 1-2 minutes, it happens about once or twice a week. Mother cannot pinpoint any specific things that trigger this behavior. After the posturing ends, the baby tends to go back to being normal with no signs of lethargy nor any other abnormalities. Mother denies any recent fever, lethargy, diarrhea, reduction in wet or dirty diapers or change in overall state</p>	YH-580-AH- YH-583-AH, YH-577-AH- YH-579-AH

DATE	FACILITY/ PROVIDER	MEDICAL EVENTS	BATES REF
		<p>Diagnosis: Infantile convulsions Failure to thrive in infant</p> <p>Medications: Gabapentin (Neurontin 250 mg/5 ml oral solution) 0.5 ml, 3 times daily.</p> <p>Follow-up: 1. Local pediatric Neurosurgery: Comment: Patient will need to see pediatric neurosurgery as an outpatient to evaluate whether he would benefit from a surgery to correct his overlapping skull bones. This may require a trip to a major city because the care is very specialized.</p> <p>2. Jena Khers: Comment: May follow up here or find a pediatric neurologist closer to home. Dr. Khera has followed patient prior to and during hospital stay.</p> <p>3. Local pediatric Ophthalmologist: Comment: Our pediatric neurologist recommended patient see a pediatric ophthalmologist to evaluate his vision as concern exists over his ability to see with both eyes.</p> <p>4. Pediatrician locally: Comment: Please ensure follow-up with a local pediatrician within one week of discharge.</p>	
12/14/YYYY - 12/19/YYYY	Provider/Hospital Name	<p>Other related records:</p> <p><i>Assessment</i> (Bates Ref: YH-658-AH- YH-708-AH, YH-712-AH- YH-720-AH, YH-726-AH)</p> <p><i>Case Management Progress Notes</i> (Bates Ref: YH-613-AH- YH-634-AH)</p> <p><i>Medication Sheets</i> (Bates ref: YH-738-AH- YH-739-AH)</p> <p><i>Nursing Notes</i> (Bates Ref: YH-641-AH- YH-649-AH)</p> <p><i>Patient Education</i> (Bates Ref: YH-710-AH- YH-712-AH)</p> <p><i>Plan of Care</i> (Bates Ref: YH-652-AH- YH-656-AH)</p> <p><i>Speech Therapy Records</i> (Bates Ref: YH-732-AH- YH-734-AH, YH-730-AH- YH-737-AH)</p>	
01/08/YYYY	Provider/Hospital	Pediatric Follow-up Visit:	SPM-21-AH- SPM-24-AH

DATE	FACILITY/ PROVIDER	MEDICAL EVENTS	BATES REF
	Name	<p>Chief Complaint: Establish care Constipation concerns Last BM Wednesday Formula feed baby Increase fussiness crying a lot Concern if baby is in pain.</p> <p>History of Present Illness: Here with mother's cousin who now has legal custody mom here, too. Has only been with them 3 days after foster placement in Danville.</p> <p>Physical Exam Nontoxic in gross appearance Irregular skull shape with overlapping sutures and crevasse appearance left side Dysconjugate gaze, +RR, no tracking TMs clear but only partly visualize Nares patent Poor head control Both hands closed with random motion Does move all extremities and flex at hips spontaneously Does not bear weight on legs</p> <p>Assessment: Abnormal EEG. Abnormal motor activity Behind on immunizations. Failed newborn hearing screen; consult with HMC audiology - passed hearing exam. 11/15. Follow-up PRN. Failure to thrive in infant History of sepsis Irritability Specific delays in development Plagiocephaly</p> <p>Plan: Refer to early Intervention Services. DTap, ____, Hepatitis B vaccine done today. We will continue to catch him up at the next visit.</p> <p>Follow-up here in 1 week.</p>	
01/11/YYYY	Provider/Hospital Name	<p>Neurology Follow-up Visit:</p> <p>Chief Complaint: Patient is a 3 month old male returning for follow-up for multiple issues.</p> <p>History of present illness: Patient is here for a 1-month follow-up and is accompanied to this</p>	WPN-29-AH- WPN-32-AH

DATE	FACILITY/ PROVIDER	MEDICAL EVENTS	BATES REF
		<p>appointment by his mother, his maternal cousin and her significant other. Together they provide his interim history. Currently, patient is in the maternal cousin's care as he was placed in foster care by Children and Youth after his last appointment and subsequent hospital admission for failure to thrive.</p> <p>They report that patient continues to gain weight and is doing better with feeds. He is now spitting up occasionally with feeds, but here is no further vomiting episodes. Foster mom reports that he is starting to wake during the night for feeds now and this is a change from a few weeks ago. They continue to be very concerned about his head shape and the fact that he is very irritable. They state that for approximately 1-2 weeks after starting the Gabapentin, he appeared more relaxed and now when he is awake, he is most often screaming. She states he is taking 6 ounces every 3-4 hours even through the night They wake him to feed if he does not wake up on his own, Foster mom reports that she will give him 3 ounces and then take a small break and burp him and then give him the next 3 ounces and he seems to be doing well with that. He is voiding at least 8-10 times per day and stools at least daily now. He was having some difficulty with constipation, but that has since resolved. They did change formula and he is currently taking Similac Sensitive and he seems to be doing better with this.</p> <p>Physical examination: Strength is antigravity and symmetric in upper lower extremities. Muscle tone was increased. There was no abnormal posturing on vertical or ventral suspension. He moves all extremities symmetrically and without difficulty. He brings both hands to midline but was not observed bring them to his mouth. No rooting reflex was observed. He was unable to hold his head up when placed in a prone position. He has good head control on traction (likely from involving increased tone).</p> <p>Assessment: Failure to thrive in infant. At risk for vision problems Abnormal finding on MRI of brain; diffuse cerebral ischemic changes. Irritability. Abnormal EEG Abnormal motor activity. Plagiocephaly.</p> <p>Plan: Referral Ophthalmology Renew Gabapentin 250 mg/5 ml Referral Neurosurgery Continue early Intervention</p>	
01/14/YYYY	Provider/Hospital	Neurosurgery Visit:	WPN-33-AH- WPN-36-AH,

DATE	FACILITY/ PROVIDER	MEDICAL EVENTS	BATES REF
	Name	<p>Chief Complaint: New patient presents in office today with concerns regarding abnormal EEG.</p> <p>History of present illness: Patient seen with custody aunt and first cousins husband and wife. Child was born and stayed in the NICU for respiratory issues. Readmission in November due to FIT and seizure activity. Despite normal ultrasound and MRI at birth, follow up November ultrasound, and CT scans in December show marked brain encephalomalacia.</p> <p>Patient is referred at this time for concerns of head shape and suture premature closure. Patient had been cared for with CYS, foster home in Danville, PA</p> <p>Physical Exam: He is unresponsive to sound, except tactile stimuli, limited. He is snorous. Cranial nerves two through 12 are intact. Suture overlap and loss of anterior fontanelle noted. There is good facial symmetry. The neck is supple with full range of motion. There is no jugular venous distention nor carotid bruit by auscultation. The chest is clear. Heart sounds show regular rate and rhythm without murmur or gallop. The abdomen is soft without masses. Extremities are without cyanosis clubbing or edema. Additional neurologic exam finds the patient with reactive pupils equal, extraocular muscles are intact without nystagmus, and a normal red reflex. Motor examination shows full strength in upper and lower extremities in all muscle groups. Sensory examination is intact to light touch. Deep tendon reflexes are symmetric, present without signs of myelopathy. Cerebellar examination finds the patient was good coordination for age. His station is consistent with CNS injury. General appearance is one of compromised health.</p> <p>Assessment: Abnormal finding on MRI of brain; diffuse cerebral ischemic changes.</p> <p>Recommendations: There is not a surgical remedy for the brain loss incurred and secondary calvarial misshapen position. I have explained this to the family. If I can be of any further assistance please do not hesitate to let me know.</p>	WN-1-REF- WN-3-REF
01/19/YYYY	Provider/Hospital	Pediatric Follow-up Visit:	SPM-25-AH- SPM-28-AH

DATE	FACILITY/ PROVIDER	MEDICAL EVENTS	BATES REF
	Name	<p>Chief Complaint: 4 Month Well</p> <p>Subjective: Interim History: Saw neurologist, didn't like her, felt rushed, felt "she had an attitude", says they asked to see one of the other neurologists and are scheduled for Feb 5.</p> <p>Assessment: Well child visit Behind on immunizations. Failure to thrive in infant. Specific delays in development. Microcephaly.</p> <p>Plan: Multiple offices visited in past few weeks with fairly large variations in weight. Have started offering feeds every 2 hours even if not giving signs of hunger so feeds are more frequent. Weight check here in 2 weeks.</p> <p>Reiterated that CYS mandates we report noncompliance and that the foster family comply with medical plan, even if they don't like the provider he needs to see neuro as neuro recommends, especially since on Gabapentin. They agree to be sure today a visit is scheduled.</p>	
01/26/YYYY	Provider/Hospital Name	<p>ER visit for nasal congestion:</p> <p>Chief Complaint: Noted nasal congestion. Mother reports wheezing. No nasal flaring. Is taking a bottle. + wet diapers. Takes temp under axilla. Has been with nasal congestion since Saturday night. Lungs sound clear cough present.</p> <p>His chest X-ray does not show pneumonia.</p> <p>Impression: Viral broncholitis</p> <p>Plan: Condition: Improved.</p> <p>Prescription: Orapreol 15 mg/5 ml, 2.5 ml daily for 5 days Benadryl Allergy 12.5 mg/5 ml, 3 ml thrice daily as needed</p> <p>Disposition: Discharged to home. Follow-up: Shawn Cooper Within 1 to 2 days.</p>	YH-746-AH- YH-752-AH, YH-744-AH- YH-746-AH, YH-753-AH- YH-766-AH
02/03/YYYY	Provider/Hospital Name	<p>Pediatric Follow-up Visit:</p> <p>Chief Complaint:</p>	SPM-29-AH- SPM-31-AH

DATE	FACILITY/ PROVIDER	MEDICAL EVENTS	BATES REF
		<p>Accompanied by: Aunt and Cousin Immunizations are up to date. Patient here for Weight Check. - Last wt on 1/19/16-11 lbs 15.5 oz</p> <p>History of Presenting Illness: Similac sensitive. 4 ounces every 3 hours. Longest between feeds. Switched from Similac sensitive liquid to powdered version and it has made him persistently spit up more. Volume more frequently, it was very minimal. Is eating puree baby foods, bananas, sweet potatoes, pears, applies without difficulty. Stooling more regularly with these solids, twice daily.</p> <p>Physical Exam: Feeds vigorously from bottle while we talk, no gagging or choking, small leak. Appears well nourished and hydrated. Microcephalic.</p> <p>Assessment: Failure to thrive in infant. Microcephaly. GERD (gastroesophageal reflux disease).</p> <p>Orders: He has gained 4 ounces in two weeks. This is a problem. We need to get more nutrition into him. Because you are reporting much more larger volume spitting up with powdered Similac Sensitive, I have signed the form asking WIC to provide the liquid. They may not do this, and we may have to continue to use the powdered.</p> <p>He needs more calories. We are going to mix his formula to 22 calories per ounce instead of the normal 20 per ounce. Use the printed instructions you were given. You can continued the pureed solids.</p> <p>Your schedule does not show a neurology appointment Your neurologist says they have not seen you. They are more than happy to find a time that works but you must call. Their number is 717-851-5503.</p> <p>Follow up here in 2 weeks for weight check. Ranitidine 15 mg/ml syrup 1 ml every 12 hours</p> <p>Plan: Messaged with Amy Briokner, peds neuro, who is contacting CYS for medical noncompliance. Used printed instructions for mixing 22 calorie formula, including showing where the ml are marked on bottle and how to follow the recipe.</p>	

DATE	FACILITY/ PROVIDER	MEDICAL EVENTS	BATES REF
02/09/YYYY	Provider/Hospital Name	<p>ER visit for fever:</p> <p>Chief complaint: Fever.</p> <p>Patient is brought in by mom. Patient was born full term but had complications which is unknown to mom. Patient had brain damage uncertain why. Due to mom not keeping up with medical care missing appointment with the doctor, the mom's cousin was granted custody. Because the cousin has children to watch overnight he noticed that over the last few days he's had a runny nose congestion and last night spiked a fever. He's been eating fine, normal amount of wet diapers but because the fever mom's cousin wanted him to be evaluated. Patient's mom and grandmother brought the child in. They've not noticed any signs of rest or distress. Since they've been here he did drink 6 ounces of milk without difficulty while here. Regarding the vomiting it was after a couple feeds last night after he had finished a bottle of milk.</p> <p>Physical exam: General: Alert, no acute distress, Patient sleeping well no signs of acute respiratory distress. When patient does intermittently cough or cry a little you can hear the congestion. Head: Atraumatic. Patient's frontal skull bone is growing asymmetrically and is underneath the parietal bones. Posterior fontanelle is soft, anterior fontanelle is closed.</p> <p>Respiratory Syncytial virus (RSV) positive</p> <p>Diagnosis: Acute bronchiolitis</p> <p>Plan: Condition: Stable. Disposition: Discharged to home. Patient was given the following educational materials; Bronchitis,</p> <p>Follow-up with: Return to ED if symptoms worsen. Follow up with primary care provider within 2 to 4 days.</p>	MH-186-AH- MH-192-AH, MH-317-REF, MH-193-AH- MH-202-AH, MH-220-AH- MH-223-AH, MH-322-REF- MH-330-REF
02/13/YYYY	Provider/Hospital Name	<p>Pediatric Follow-up Visit:</p> <p>Chief Complaint: Follow up RSV</p> <p>History of present illness: Patient present today accompanied by New Foster mom. Was told he was seen at ED and diagnosis with RSV. No medication was given to foster mom. Breathing seems better than it was 3 days ago when baby was received by foster mom. Has been massaging babies lungs.</p>	SPM-32-AH- SPM-34-AH

DATE	FACILITY/ PROVIDER	MEDICAL EVENTS	BATES REF
		<p>Foster mother was not aware of the change to 22 calorie per ounce formula. He is taking between four and six ounces at least every three hours.</p> <p>She also only recently became aware of the baby taking Gabapentin and was not aware until today of the Ranitidine.</p> <p>Reviewed Emergency Department note from 1/26/16 and neurology note from 1/11/16.</p> <p>Assessment: Failure to thrive in infant. Microcephaly. Nasal congestion.</p> <p>Orders: Hydrocortisone 1% external Ointment</p> <p>Plan: Mix formula according to directions to provide 22 calories per ounce and offer as much as the baby will take. Normal saline (salt water) nose drops one or two in each nostril followed by suctioning as needed for nasal congestion. Continue Gabapentin solution, one 1 ml three times a day. Continue Ranitidine syrup one mL every 12 hours. Please keep follow up visit scheduled for 2/17/16.</p>	
02/17/YYYY	Provider/Hospital Name	<p>Pediatric Follow-up Visit:</p> <p>Chief Complaint: Weight Check Previous Weight: 12 lbs 9 oz on 02/13 Weight Gain: 9.5 oz</p> <p>History of present illness: New foster care Fortifying 22 cal, feeding 6 ounces every 3 hours, up to for or a little more at night. Burps well Foster parents had been told he spit up a lot but he rarely does. Foster parents had been told he would need to be woken at night because he does not signal when hungry but they see him clearly give signals every 3-4 hours and be satisfied after. Foster parents had been told he did not respond well to social interaction and soothing but they see that he does. Pooping at least once a day Lots of wet diapers Getting tummy time now</p> <p>Vital Signs: Weight: 13 lb 2.5 oz; 0-24 Weight Percentile 1%</p>	SPM-35-AH- SPM-37-AH

DATE	FACILITY/ PROVIDER	MEDICAL EVENTS	BATES REF
		<p>Physical Exam: Fussy, usual baseline relative hypertonic, extended arms plagiocephaly Scant clear rhinorrhea</p> <p>Assessment: Failure to thrive in infant. GERD. Nasal congestion.</p> <p>Orders: Continue feeding at the 22 calorie concentration. Let him feed as much as he wants. 6 ounces is fine, remember that sometimes he will may spit up more if he eats too many ounces, he may need to be paced. It is fine not to give the Ranitidine if you continue to not see the painful spitting up that was seen in the past. ER diagnosed him with RSV but his lungs are clear, only a tiny bit of runny nose, and his ears look fine. He should not have any new or worsening symptoms. If he does we will see him again. See neurology as scheduled on the 26th. Well check here as scheduled next month, sooner if any concerns.</p> <p>Plan: I get the impression the new foster parents are very much on the wall. Then attention to details. Already seeing improvement in weight gain after improving both the frequency and caloric content of the feeds. Reviewed with family the need to continue to provide extra calories to catch up on what has to this point than a longer period slow weight gain. Reviewed the importance of following up with the specialists. Already saw Dr. waiting on report.</p>	
02/26/YYYY	Provider/Hospital Name	<p>Neurology Follow-up Visit:</p> <p>Chief Complaint: Patient is a 5 month old male returning for follow-up for neonatal sepsis complicated by seizures and respiratory difficulties.</p> <p>History of present illness: Patient is here for neurological followup. He is accompanied to today's appointment by his mother and by Keisha Cross and this is his current foster mother. Keisha is a distant relative to patient's biological mother. Interim history is obtained through reviewing pediatrician and Emergency Department records as well as their input.</p> <p>Patient has been in the care of Ms. Cross since I believe February 10, 2016. She reports that she was never told by Children and Youth Services that he was on Gabapentin and so he missed a couple of days of the medication. She then started giving it to him and does report that he seems very calm and relaxed when he is with her. He is not</p>	WPN-37-AH- WPN-40-AH

DATE	FACILITY/ PROVIDER	MEDICAL EVENTS	BATES REF
		<p>having prolonged crying episodes and is feeding well. She is giving him tummy time and he is starting to lift his head and also trying to scoot himself forward on his belly. He is taking approximately 6 ounces every 4 hours and has very minimal spat-ups. He is voiding at least 8-10 times per day and has stools at least once per day. They are feeding him 22-calorie formula. He has had a 1-pound weight gain in 9 days.</p> <p>Foster mother reports that he is trying to rollover and they are hearing more cooing sounds from him. She is not sure if he can see or track objects and he is not yet regarding face or focusing his eyes.</p> <p>She reports Early Intervention Services start with her in 2 weeks and they see the pediatrician March 21, 2016, for follow-up. They have no other concerns for him and deny witnessing any seizure-type activity. Mother currently has visitation 2 times per week.</p> <p>Physical Exam: He is awake and quiet and relaxed during the appointment. He did fast when they were getting him dressed but other with there was no irritability noted. Weight is on the chart at the 6th percentile, head circumference remains less than 1st percentile, length is at the 1st percentile.</p> <p>General examination: Head is microcephalic and plagiocephaly. Anterior fontanelle is not appreciated on exam. Left a subtle flattening is noted with prominent overriding sutures. Reflexes are symmetric and intact. Funduscopic examination was not able to be performed due to his continuously roving eyes. Heart was regular rate and rhythm without murmur. Lungs clear to auscultation bilaterally. He has significant nasal congestion and noisy breathing. Abdomen is soft, nontender nondistended with no mass or organomegaly. There is no scoliosis or sacral dimple. There were no neuro cutaneous markers. Mongolian spots are present upper back and over sacral spine.</p> <p>Neurologic examination: He was or equal, round react to light Extraocular movements were intact. Visual field acuity could not be assessed. Face is symmetric and intact. Tongue was midline and palate elevation was equal. Strength is antigravity and symmetric in upper lower extremities. Overall muscle tone was increased. There was no abnormal posturing on vertical or ventral suspension. He moves all extremities symmetrically and without difficulty. He brings both hands to midline and his mouth. No rooting reflex was observed. He was able to hold his head briefly when placed in the prone position. He has good head control in traction (likely from involving increased muscle tone).</p> <p>Deep tendon reflexes are 3+ and symmetric in upper and lower extremities bilaterally, Moro, palmar and plantar reflexes were intact.</p>	

DATE	FACILITY/ PROVIDER	MEDICAL EVENTS	BATES REF
		<p>Gait is not applicable. Plantar response is up going bilaterally. Sensory examination was intact light touch. There was no tremor or titubation or abnormal motor movements noted.</p> <p>Assessment: Abnormal EEG Abnormal finding on MRI of brain; diffuse cerebral ischemic changes. Failure to thrive in infant. Microcephaly.</p> <p>Orders: Renew Gabapentin 250 mg/5ml Solution take 1.5 ml 3 times daily 1. I increased the Gabapentin to 1.5 ml three times a day. 2. Continue with the feeding schedule/increased calories he is getting. 3. Continue with Early intervention therapies. 4. I will see him back in 2 months.</p>	
03/01/YYYY	Provider/Hospital Name	<p>Pediatric Follow-up Visit:</p> <p>Chief Complaint: Congestion-patient is not coughing a lot but has a lot of nasal congestion Low grade fever- 99.1 yesterday Vomiting-started yesterday evening caregiver stated he threw up 4 items yesterday - none since. Patient did not drink very well yesterday doing ok today</p> <p>History of present illness: Had RSV last month Congestion cleared and seemed to be getting better Then congestion returned after returning from mom's house Cough when eats only, otherwise no cough Tmax 99.1 yesterday Sounds better overall than he did Vomited a lot of mucous yesterday about 4 times Still eating well though Voiding and stooling well Sleep excellent</p> <p>Vital Signs: Weight: 14 lb 13 oz; 0-24 Weight Percentile 11%</p> <p>Assessment: Nasal congestion GERD (gastro esophageal reflux disease) Viral respiratory illness</p> <p>Orders: Patient looks great on exam</p>	SPM-38-AH- SPM-41-AH

DATE	FACILITY/ PROVIDER	MEDICAL EVENTS	BATES REF
		<p>He is well hydrated Lungs sound good, all congestion is in his nose and throat areas Encourage feedings - he may do better with smaller more frequent feedings until he is feeling better or take longer to finish a bottle You can give him Pedialyte if not tolerating formula Continue nasal saline with suctioning prior to eating and sleeping Cool mist humidifier in his room Monitor for fever</p>	
03/01/YYYY	Provider/Hospital Name	<p>Lab report: Collected date: 03/01/YYYY Source: Nasopharyngeal Positive for rhinovirus/Enterovirus</p>	YH-797-AH, YH-796-AH
03/14/YYYY	Provider/Hospital Name	<p>Referral report: Referral peds feeding (OT/speech) eval and treat Frequency and duration: Per clinical discretion</p>	WPR-28-AH- WPR-30-AH
03/21/YYYY	Provider/Hospital Name	<p>Pediatric Follow-up Visit: Chief Complaint: Accompanied by Foster Mom, Mother Pentacel, Prevnar, Rotateq Physical Exam General: Alert 6 month old male in no acute distress and interactive. Head: Microcephalic with overriding sutures. AF closed. Assessment: Abnormal motor activity Well child visit Nasal congestion Abnormal finding on MRI of brain diffuse cerebral ischemic changes. Specific delays in development Microcephaly Excellent weight gain. Plan: Foster mom is doing an excellent job with this baby. Return to clinic in 4 weeks for 2nd flu vaccine and weight follow up.</p>	SPM-42-AH- SPM-46-AH
03/24/YYYY	Provider/Hospital Name	<p>Speech therapy/feeding evaluation: Oral motor assessment: Facial symmetry noted Oral structures appear healthy and pink Palate is round and intact The patient is edentulous, which is age appropriate at this time The patient was able to establish a strong non nutritive</p>	WPR-22-AH- WPR-27-AH, WPR-14-AH- WPR-19-AH

DATE	FACILITY/ PROVIDER	MEDICAL EVENTS	BATES REF
		<p>suck with an adequate tongue copying and intraoral pressure on a gloved finger. He was offered the Dr. Brown's bottle with a level 3 nipple that was not manually cut secondary to the size of the manually cut nipple. No cereal was added to this bottle. The patient was observed to establish a strong intraoral pressure for suction with adequate milk transfer, however, with the level 3 Dr Brown's nipple the flow was slightly too fast and he had difficulty establishing a consistent intermittent suck-swallow-breathe pattern that he has been able to establish in the past. At that time the nipple was changed to a level 2 nipple that did result in adequate milk transfer, adequate suction and intraoral pressure establishment and adequate and safe milk transfer that did allow for the integrity of the suck-swallow-breathe pattern to remain intact during feeding. The patient had just eaten about an hour and a half prior to his evaluation today. Therefore, he was not significantly hungry and did not ultimately consume more than an ounce and a half for today's visit. The patient was also offered a spoon with stage 1 baby sweet potatoes. The patient was observed to open his mouth and accept the spoon without difficulty. The patient sucked the puree off of the spoon which is an age appropriate response to spoon feedings at this time. Ultimately, the patient does not exhibit any oral dysphagia at this time and is using adequate oral motor skills to support both bottle feeding and spoon feeding at this time.</p> <p>Feeding Assessment: The patient was held by the foster mom in a cradle like position for bottle feeding and in an upright position for spoon feedings. The patient demonstrated adequate milk transfer was the bottle and adequate acceptance of the spoon and cleaning of the spoon with minimal lingual thrusting during the time of the evaluation to accept both foods.</p> <p>The patient was not extremely hungry as he had just feed approximately an hour and a half before coming to the appointment today, but was able to take approximately 1-1/2 ounces of formula and approximately 5 infant spoonfuls of the baby 1 sweet potatoes.</p> <p>Medical diagnoses: Failure to thrive, feeding difficulties in infancy, microcephaly, specific delays in development.</p> <p>Plan: The patient does not qualify for skilled intervention with a speech language pathologist for feeding at this time.</p>	
04/05/YYYY	Provider/Hospital Name	<p>Pediatric Follow-up Visit:</p> <p>Chief Complaint: Accompanied by: Foster parents Patient here for stuffy nose Sneezing possible allergies? Cough</p> <p>Duration: Started yesterday</p>	SPM-49-AH-SPM-51-AH, YH-800-AH

DATE	FACILITY/ PROVIDER	MEDICAL EVENTS	BATES REF
		<p>Vital Signs: Weight: 17 lb 10.5 oz; 0-24 Weight Percentile 42%</p> <p>Assessment: Cough. Viral respiratory illness. Wheezing.</p> <p>Orders: Respiratory viral detection panel X-ray chest</p>	
04/05/YYYY	Provider/Hospital Name	<p>Lab report:</p> <p>Collected date: 04/05/YYYY Source: Nasopharyngeal</p> <p>Positive for RSV, Rhinovirus/Enterovirus</p>	SPM-47-AH
04/05/YYYY	Provider/Hospital Name	<p>X-ray of chest:</p> <p>Indication: Cough, wheezing.</p> <p>Impression: Mild bronchiolitis versus reactive airway disease. The findings were verbally given to Laurie Deller, LPN of Springdale peds, per Katherine Jacobs on 4/5/16 at 7:23 PM.</p>	YH-801-AH
04/08/YYYY	Provider/Hospital Name	<p>Pediatric Follow-up Visit:</p> <p>Chief Complaint Accompanied by: Foster Mother Patient is here for a recheck of his breathing. Foster mom states that it has improved but still sounds wheezy.</p> <p>History of present illness: Here for follow up of RSV bronchiolitis. Is doing better per foster mom. Is eating well. Taking bottles well. Urine and BM normally. Coughing is improving.</p> <p>Vitals: Weight: 17 lb 7 oz; 0-24 Weight Percentile 37%</p> <p>Assessment: RSV/bronchiolitis.</p> <p>Follow-up: RTC in 1 week for follow up. Continue saline drops up his nose before every bottle and before bed. Continue cool mist humidifier. Call immediately for any poor feedings, decreased urine output or any</p>	SPM-52-AH- SPM-55-AH

DATE	FACILITY/ PROVIDER	MEDICAL EVENTS	BATES REF
04/19/YYYY	Provider/Hospital Name	<p>increased work of breathing (nasal Flaring, grunting, retractions.)</p> <p>Pediatric Follow-up Visit:</p> <p>Chief Complaint: Follow up for RSV/Bronchiolitis Foster mother stated patient is doing wonderful however patient had a visitation with his birth mother yesterday and foster mother stated she now believes he has pink eye. Foster mother wants to know if patient can have immunizations he is behind on or if she should wait until patient is 100%</p> <p>History of present illness: Right eye crusty this AM, junky No swelling Saw Katie for RSV and rhinovirus last week Doing much better Still a little congested but much improved, using saline Appetite good.</p> <p>Assessment: RSV/bronchiolitis resolving.</p> <p>Keep well check next week but we will go ahead and give him 3rd round of vaccines today as you requested due to traveling.</p> <p>Administered: DTaP-IPV/Hib (Pentacel), Frevnar 13, Rotavirus (RotaTeq), Fluzone Quadrivalent 0.25 ml</p>	SPM-56-AH- SPM-58-AH
05/06/YYYY	Provider/Hospital Name	<p>Pediatric Follow-up Visit:</p> <p>Chief Complaint: Accompanied by: Mother Cough, nasal congestion</p> <p>History of present illness: Has follow up with neuro 5/16 and plastics (HMC) Started Monday with nasal congestion. Is coughing but non-productive.</p> <p>Physical exam: Weight: 18 lb 11.5 oz; 0-24 Weight Percentile 49%</p> <p>Assessment: Microcephaly Acute upper respiratory infection. Purulent rhinitis.</p> <p>Plan: Patient looks good on evaluation today. Saline drops up nose before every bottle and before bed, cool mist</p>	SPM-59-AH- SPM-61-AH

DATE	FACILITY/ PROVIDER	MEDICAL EVENTS	BATES REF
		humidifier in bedroom at night Nasal flaring, grunting retractions or with any fevers. I would like to see patient back for a follow up visit in 1 week.	
05/16/YYYY	Provider/Hospital Name	<p>Neurology Follow-up Visit:</p> <p>Chief Complaint: Patient is a 8 month old male returning for follow-up for neonatal sepsis complicated by seizures and respiratory difficulties</p> <p>Physical Exam: He is awake and quiet and relaxed during the appointment. He is heard laughing and trying to coo/make noises during the visit. Weight is on the chart at the 50th percentile, head circumference remains less than 1st percentile, length is at the 8th percentile.</p> <p>General examination: Head is micro cephalic and plagiocephalic. Anterior fontanelle is not appreciated on exam. Left occipital flattening is noted with prominent overriding sutures. Reflexes are symmetric and intact. Fundoscopic examination was not able to be performed due to his continuously roving eyes. He has significant nasal congestion and noisy breathing. Mongolian spots are present upper back and over sacral spine.</p> <p>Neurologic examination: Pupils are equal, round and react to light. Visual field acuity could not be assessed. Face is symmetric and intact. Tongue was midline and palate elevation was equal.</p> <p>Strength is antigravity and symmetric in upper lower extremities. Overall muscle tone was increased. There was no abnormal posturing on vertical or ventral suspension. He moves all extremities symmetrically and without difficulty. He brings both hands to midline and his mouth. He was able to hold his head up briefly when placed in the prone position. He has good head control on traction (likely from involving increased muscle tone).</p> <p>Deep tendon reflexes are 3+ and symmetric in upper and lower extremities bilaterally. Mororeflex persists.</p> <p>Gait is not applicable. Plantar response is equivocal. Clonus is noted bilaterally. Sensory examination was intact light touch. There was no tremor or titubation or abnormal motor movements noted.</p> <p>Assessment: Abnormal EEG Microcephaly Specific delays in development Hypertonia Torticollis, acquired</p>	WPN-41-AH- WPN-44-AH

DATE	FACILITY/ PROVIDER	MEDICAL EVENTS	BATES REF
		<p>Plan: Renew Gabapentin 250 mg/5ml Oral Solution; take 2 ml three times daily. Please increase the Gabapentin dose to 2 mls three times/day. Please have hereby send us records after he is seen there in May. Please call Ophthalmology and reschedule his appointment sooner than October due to vision concerns. I will see him back in 3 months.</p>	
05/17/YYYY	Provider/Hospital Name	<p>Pediatric Follow-up Visit:</p> <p>Chief Complaint: Accompanied by: Mother, Foster Parents Patient here for cough and congestion Duration: has had on and off for a while</p> <p>History of present illness: RSV in the past. Was seen 5/6 with URI symptoms again. Nasal congestion and irritability. Here for follow up Still with nasal congestion. + coughing occasionally (3-5 times daily)</p> <p>Vital Signs: Height 67.5 cm, 0-24 Length Percentile; 8% Weight: 8.60 kg, BMI: 18.9 kg/m²</p> <p>Physical Exam: Constitutional: Mildly ill appearing. Left TM: Purulent drainage in canal. TM red.</p> <p>Assessment: Acute upper respiratory infection. Nasal congestion Acute suppurative otitis media of left ear with spontaneous rupture of tympanic membrane</p> <p>Orders: Amoxicillin 400 mg/5ml, Ofloxacin 0.3% ophthalmic solution Water precaution in left ear Drops x 7 days Antibiotics twice daily x 10 days.</p> <p>Plan: Patient/Parent understands all instructions and precautions. Rest and push fluids. May use probiotics while on antibiotics, at least 1 billion CFU's/day, continue them for 7-14 days after finishing medication. Discussed side effects of medications.</p>	SPM-62-AH- SPM-65-AH

DATE	FACILITY/ PROVIDER	MEDICAL EVENTS	BATES REF
05/31/YYYY	Provider/Hospital Name	<p>Pediatric Follow-up Visit:</p> <p>Chief Complaint: Accompanied by: Foster Mom Immunizations are up to date. Patient here for follow up breathing</p> <p>History of present illness: Past 5 days vomits after eating Cough is better Still has stuffy nose.</p> <p>Vitals: Weight: 20 lb 0.5 oz; 0-24 Weight Percentile 63%</p> <p>Assessment: GERD (gastroesophageal reflux disease) Acute suppurative otitis media of left ear with spontaneous rupture of tympanic membrane. Resolved Acute upper respiratory infection; Resolved</p> <p>Follow-up as needed for physical.</p> <p>Plan: Increased Ranitidine to 1.75 ml twice a day Add Cetirizine 2.5 ml at bed to see if helps with congestion Ears are better.</p>	SPM-66-AH- SPM-69-AH
06/09/YYYY	Provider/Hospital Name	<p>Pediatric Follow-up Visit:</p> <p>Chief Complaint Nasal congestion</p> <p>History of present illness: Last seen on 5/31/YYYY- prescribed allergy medication. Makes him tired. Always congested. Was improving. When he goes to catholic charities- tends to get sick. Started back there last week and now worse again.</p> <p>Vital Signs Weight: 20 lb 8.5 oz ; 0-24 Weight Percentile 68%</p> <p>Physical exam: Constitutional: Tactypneic, noisy breathing, occasional cough Head: Microcephaly. Ears: Right TM: Normal, cerumen removed with curette: Left TM: Normal. Nose: Nasal congestion. Clear rhinorrhea. Respiratory: Bilateral Wheeze. Coarse Breath Sounds, tachypneic. Neuro: Delayed, increased tone.</p>	SPM-71-AH- SPM-74-AH

DATE	FACILITY/ PROVIDER	MEDICAL EVENTS	BATES REF
		<p>Assessment Specific delays in development Microcephaly GERD (gastroesophageal reflux disease) Wheezing Cough</p> <p>Orders: Pulse ox Albuterol Sulfate (2.5 mg/3 ml) 0.083% Inhalation Nebulization - Nebulizer every 4 hours as Needed.</p>	
06/09/YYYY	Provider/Hospital Name	<p>X-ray of chest:</p> <p>Indication: Cough and wheezing</p> <p>Impression: No acute process identified.</p>	SPM-70-AH, YH-805-AH
06/21/YYYY	Provider/Hospital Name	<p>Pediatric Follow-up Visit:</p> <p>Chief Complaint: Accompanied by: Mother, Foster Mom, Grandmother</p> <p>Vital Signs: Height 27 in. Weight: 20 lb 8.5 oz Weight Percentile 64%; 0-24 Length Percentile 6% Head circumference 14.88 inch, percentile 1%</p> <p>Physical Exam: General: Alert 9 month old male in no acute distress and interactive. Head: Microcephalic, plagiocephaly Nose: Nares patent. + clear rhinorrhea Respiratory: +rhonchi throughout lung fields.</p> <p>Assessment: Well child visit Rhonchus; chronic Hypertonia GERD (gastroesophageal reflux disease) Specific delays in development Microcephaly</p> <p>Orders: Referral Pulmonary Follow up for 12 Month Well Child Check.</p>	SPM-75-AH- SPM-78-AH
07/18/YYYY	Provider/Hospital Name	<p>Pediatric Follow-up Visit:</p> <p>Chief Complaint: Accompanied by: Mother</p>	SPM-79-AH- SPM-81-AH

DATE	FACILITY/ PROVIDER	MEDICAL EVENTS	BATES REF
		<p>Patient here for congestion. Immunizations are up to date.</p> <p>History of present illness: Since starting humidifier nasal congestion is already improving. Mostly sounds to be in the sinuses.</p> <p>Vital Signs: Weight: 22 lb 1 oz; 0-24 Weight Percentile 78%</p> <p>Physical Exam: Baseline microcephaly Hypertonic Moist oral mucosa with copious thick white postnasal drip Audible nasal congestion with visible white rhinorrhea Heart regular rate and rhythm overridden by coarse upper airway sounds Lungs fields themselves are symmetric and well aerated but with upper airway sounds transmitted.</p> <p>Assessment: Acute upper respiratory infection.</p> <p>Orders: Sodium Chloride 0.65 % Nasal Solution; 1 spray in each nostril every 2 hours for nasal congestion and drainage. Lots of nasal congestion and drainage. Continue the humidifier. Nasal saline every 2-3 hours. Bulb suction after.</p>	
08/18/YYYY	Provider/Hospital Name	<p>Neurology Follow-up Visit:</p> <p>Chief Complaint: Patient is a 11 month old male who is returning for a follow-up visit for neonatal sepsis complicated by seizures and respiratory difficulties.</p> <p>History of present illness: Patient is here for neurodevelopmental follow-up. He has a history of neonatal sepsis subacute by seizures respiratory difficulties. He has had an abnormal EEG but to date has not had seizure activity. He is microcephalic. He is here with his biological and Foster mother's but remains in care of Foster mother full time. She provides his interim history. He was last in the office in May 2016.</p> <p>He is currently on Gabapentin for neuro- irritability however he is outgrown his current dose and is not having any increased irritability, difficulty with feeds, sleeping, etc. He has gained a significant amount of weight most likely secondary to the medication. Foster mother reports he is tracking her face, smiling socially and response to them, trying to rollover and hold his head up when he is on his belly. He is</p>	WPN-45-AH- WPN-48-AH

DATE	FACILITY/ PROVIDER	MEDICAL EVENTS	BATES REF
		<p>eating baby and table foods and continues on formula however she has started small amounts of milk.</p> <p>She denies seeing any evidence of seizure activity. He was seen by Hershey neurosurgery who determined there is no craniosynostosis however her skin is significantly abnormal with prominent suture lines/bridges but he is not a candidate for reconstructive surgery.</p> <p>Vital Signs: Height 68.58 cm. Weight 10.37 kg, BMI: 22.06, BSA: 0.42 ; 0-24 Length Percentile 1%; 0-24 Weight Percentile 81%</p> <p>Physical Exam: General examination: The patient was alert, active and in no distress. Anterior fontanelle is not appreciated. Head is microcephalic with prominent suture ridges noted. There is flattening of the posterior occipital region. Red reflexes are symmetric and intact. Funduscopic examination was not completed due to roving eyes. He is overweight. Length is at the 1st percentile, weight is at the 81st percentile, height is at the 1st percentile.</p> <p>Neurologic examination: Pupils are equal, round and reactive to light. Eyes are roving and did not fix and follow. Extraocular movements were intact. Visual fields and acuity could not be assessed. Face is symmetric and intact. Tongue was midline and palate elevation was equal.</p> <p>Strength is antigravity and symmetric in upper lower extremities. Muscle tone was increased in extremities. There was no abnormal posturing on vertical or ventral suspension. He has good head control on traction, likely from increased tone. Today he did not lift his head off the exam table when in the prone position.</p> <p>Deep tendon reflexes were 2+ and symmetric in upper and lower extremities. Palmar and plantar, grasps are present. Lateral prop and parachute reflexes were absent.</p> <p>Plantar response is upgoing bilaterally. Sensory examination was intact light touch. He brings hands to midline and his mouth but movement is not orchestrated. Clonus is noted bilaterally. Sensory examination was intact to light touch.</p> <p>Assessment: Abnormal EEG Abnormal finding on MRI of brain; diffuse cerebral ischemic changes Microcephaly Torticollis, acquired</p>	

DATE	FACILITY/ PROVIDER	MEDICAL EVENTS	BATES REF
		<p>Orders Renew Gabapentin 250 mg/5 ml Oral Solution; take 2 ml three times daily. EEG due to microcephaly. Please schedule after the 28th as family will be out of town until then. Decrease the Gabapentin to 2 ml's three times per day starting today. I will call you with the EEG results - typically a few days after the test. I will see him back in 3 months.</p>	
08/30/YYYY	Provider/Hospital Name	<p>EEG report:</p> <p>Reason for study: The patient is an 11-month-old with history of hypoxic ischemic injury at birth, and this has resulted in significant developmental delays and microcephaly. He had an episode in the office of persistent head deviation to the left. Evaluate for seizures.</p> <p>Impression: This is an abnormal tracing due to the following: 1. Continuous slowing in the left frontal region with spikes and sharp waves from the left frontal, left frontotemporal central regions. 2. Suppression in the right posterior temporal and central parietal region as well as sharp waves in the right frontal and right frontotemporal regions. 3. Bifrontal spikes. 4. Myoclonic type seizures, which are brief with arm extension and eyes opening associated with bifrontal spikes with a wide field of spread. 5. Abnormal background rhythm during wakefulness and sleep is also difficult to distinguish when the patient is awake and asleep based on the electrographic activity.</p> <p>This EEG is consistent with a potential for multifocal epilepsy, generalized epilepsy as manifested by the myoclonic jerks and encephalopathy with the slowing and suppression and lack of well-formed background rhythm.</p>	YH-811-AH- YH-812-AH, YH-810-AH
09/19/YYYY	Provider/Hospital Name	<p>Pediatric Follow-up Visit:</p> <p>Chief Complaint Accompanied by: Foster parents and Mother Patient here for 12 month WCH</p> <p>Subjective: Sees Neurology. Seizure disorder. Sees Amy Brinkner. She is adjusting his meds. Saw ENT 8/29/16. Given nasal steroid. Large adenoids. Also given Cetirizine.</p> <p><i>*Reviewer's comment: Details related to ENT visit on 08/29/YYYY are</i></p>	SPM-82-AH- SPM-86-AH

DATE	FACILITY/ PROVIDER	MEDICAL EVENTS	BATES REF
		<p><i>not available for review.</i></p> <p>Vital Signs: Height 27.63 in. Weight 23 lb 12.5 oz, BMI: 21.90, BSA: 0.43 ; 0-24 Weight Percentile 84%; 0-24 Length Percentile 1%</p> <p>Physical Exam: General: Alert 12 month old male in no acute distress. Developmental delay. Able to sit with support. Head: Microcephalic. Eyes: Retinal reflex bilaterally.</p> <p>Assessment: Well child visit.</p> <p>Orders: Pulse Ox Counseling for recommended immunizations completed. Vaccines given at this time: Administered: Varivax, Hepatitis A PED, MMR</p> <p>Follow up for 15 Month Well Child Check Follow up in 6 months for 18 Month Well Child Check Follow up with his Neurologist, ENT and Pulmonologist.</p>	
11/01/YYYY	Provider/Hospital Name	<p>Pediatric Follow-up Visit:</p> <p>Chief Complaint: Accompanied by: Foster mother Immunizations are up to date. Patient here for heavy breathing Fussy, not eating, congestion. Duration: 5 days getting worse.</p> <p>Vital Signs: Weight 24 lb 1.5 oz; 0-24 Weight Percentile 79%</p> <p>Physical Exam: Constitutional: Noisy breathing from nasal congestion Head: Microcephalic Right and left TM: Serous effusion behind TM Nose: Nasal congestion with erythema or nasal turbinatous</p> <p>Assessment: Non intractable epilepsy without status epilepticus, unspecified epilepsy type. Viral infection. Nasal congestion. Vomiting.</p>	SPM-87-AH- SPM-90-AH

DATE	FACILITY/ PROVIDER	MEDICAL EVENTS	BATES REF
		<p>Orders: Nasal congestion is due to enlarged adenoids along with concurrent viral infection. Continue to use nasal saline and suctioning frequently and Flonase as prescribed. Ensure adequate fluid intake. Use Albuterol nebulizer every 3-4 hours while awake. For the increase in seizure activity, hopefully the increase in dose of Keppra will start to help control these symptoms. Follow up with Neurology appointment later this week. Follow up with Hershey ENT about Adenoids and tympanostomy tubes.</p>	
11/03/YYYY	Provider/Hospital Name	<p>Neurology Follow-up Visit:</p> <p>Chief Complaint: Patient is a 13 month old male returning for follow-up for neonatal sepsis completed by seizures and respiratory difficulties.</p> <p>History of present illness: Patient is here for follow-up of microcephaly, associated abnormal delays, and epilepsy. He appears to have good seizure control however the DC episodes of arm stiffening but no other abnormal motor movements. It is not a sudden spasm or jerking. He's had no convulsions.</p> <p>Foster mother reports patient is trying to feed himself brings his hands to his mouth, tries to hold a spoon when feeding, and is starting to get himself up as if to crawl.</p> <p>Currently he is sitting in his foster lather's lap without much movement. Foster mother showed me a video of him "trying to feed himself upon review of a second video, he is holding onto Foster mother's hand while she is feeding him with a spoon. He made no attempts to do that himself.</p> <p>Vital Signs: Height 74.5 cm. Weight: 11.29 kg, BMI: 20.35</p> <p>Physical Exam: He is awake and in no distress. Vital signs are noted above. He is overweight. Head was microcephalic, atraumatic. Eyes are anicteric and there was no conjunctival injection.</p> <p>On neurological examination, the patient was awake but did not track visually. He made sounds intermittently. Ductions are full without nystagmus or ptosis. He did not smile. Tongue was midline without fasciculations. Gag is present.</p> <p>On motor examination, global hypotonia was noted. Plantar and palmar grasps are present. There is no head lag on traction. He had no tremor or titubation. He did not bring his hands to mouth are midline.</p>	WPN-49-AH- WPN-52-AH

DATE	FACILITY/ PROVIDER	MEDICAL EVENTS	BATES REF
		<p>He cannot hold his head up off the exam table when placed prone. He did not sit independently. He made no attempts to roll over when on his back or his belly. Lateral prop and parachute reflexes are absent.</p> <p>He did not reach for objects. Sensation was intact to light touch. Reflexes are 2+ bilaterally in the upper and lower extremities and planters were down going bilaterally. Gait is not applicable. He did not exhibit much extremity motor movement during this visit.</p> <p>Assessment: Abnormal EEG. Microcephaly. Hypertonia Epilepsy seizure, nonconvulsive, generalized.</p> <p>Orders: Renew Levetiracetam 100 mg/ml Oral Solution; Take 2 ml twice a day ongoing. Continue on the Keppra at current dose. I am going to talk with Dr. Khara about adding/changing medications due to concern for persistent seizures. I will call you with the results. I will see him back in 3 months or sooner if needed.</p>	
11/15/YYYY	Provider/Hospital Name	<p>EEG report:</p> <p>Reason for study: Patient is a 14-month-old with epilepsy and developmental disabilities related to neonatal encephalopathy. Evaluate for epileptiform activity, as the patient is having muscle body jerks.</p> <p>Impression This is an abnormal tracing due to the presence of the following:</p> <ol style="list-style-type: none"> 1. Myoclonic jerks associated with bifrontal high-amplitude spikes with after-going slow waves at times appearing to be a generalized discharge. 2. No posterior discernible background rhythm with suppression of activity from the bilateral centroparietal, temporoparietal and occipital regions. 3. Epileptiform spikes and sharp waves in the frontal regions occurring synchronously and asynchronously in the left temporal region. 	YH-816-AH- YH-817-AH, YH-815-AH
12/06/YYYY	Provider/Hospital Name	<p>Lab report:</p> <p>Valproic acid 145.8 (H)</p>	WPN-104-AH - WPN-107-AH, YH-820-AH- YH-821-AH
12/09/YYYY	Provider/Hospital Name	<p>Pediatric Follow-up Visit:</p> <p>Chief Complaint: Congested Cough Nasal Congestion</p>	SPM-91-AH- SPM-94-AH

DATE	FACILITY/ PROVIDER	MEDICAL EVENTS	BATES REF
		<p>Nasal saline spray almost 12 times per day Using inhaler Suctioning 12 times per day Last neb treatment given this AM Fever present this AM Max T 100.3 taken rectally.</p> <p>Vital Signs: Weight; 26 lb 4 oz ; 0-24 Weight Percentile 91%</p> <p>Physical Exam: Audible loud nasal congestion. Moist oral mucosa with copious white postnasal drip. Left tympanic membrane erythema and pus. Hypertonic.</p> <p>Assessment: Spastic quadriplegia Nasal congestion Upper respiratory infection Left otitis media</p> <p>Orders: Amoxicillin 400 mg/5ml Oral Suspension Reconstituted; 6 ml Every twelve hours. Continue cough assist (cofflator). Continue his usual medicines. Continue Albuterol every 4 hours. Amoxicillin for the ear infection. Follow up with me Monday. See us over the weekend if getting worse.</p>	
12/12/YYYY	Provider/Hospital Name	<p>Pediatric Follow-up Visit:</p> <p>Chief Complaint: Follow Up Cough has improved Nasal congestion still present Patient is vomiting at times Noticed when patient gets worked up or in certain situations he is known to vomit.</p> <p>History of present illness: Family reports very good improvement. Mostly still nasal congestion. Cough is milder. Feeds going well as usual. Still using cough assist device. Three times daily. Still continuing his chronic medications. No Albuterol yet today.</p> <p>Physical Exam: Clear rhinorrhea</p>	SPM-95-AH- SPM-98-AH

DATE	FACILITY/ PROVIDER	MEDICAL EVENTS	BATES REF
		<p>Assessment: Upper respiratory infection.</p> <p>Orders: Renew Sodium Chloride 0.65 % Nasal Solution; 1 spray in each nostril every 2 hours for nasal congestion and drainage. He is improving and should only continue to improve. Continue your current routine. Follow up as needed.</p>	
12/16/YYYY	Provider/Hospital Name	<p>Lab report: Valproic acid 90.3</p>	YH-827-AH, YH-826-AH
12/22/YYYY	Provider/Hospital Name	<p>Pediatric Follow-up Visit:</p> <p>Chief Complaint: Here for 15 month well child</p> <p>Subjective Interim History: Seizure disorder - Had high levels of Valproate, last level checked on 12/16 - back to normal. Patient currently being transition from Valproic acid to Topiramate. Tolerating this well. Acute OM left ear - finished course of Amox BID x 10 days - doing well, no fevers, no ear pulling. Recent Barium swallow - Done at HMC, noted to have some aspiration with thin liquids. Advised to thicken liquids to nectar consistency. Report is pending.</p> <p>Developmental: Based on FEDS Score Form is not developing properly. Does Not listen to a story, imitate activities, bring objects over to show you, indicate wants by pulling, pointing, or grunting, say 2 to 3 words (not Dada/Mama) with meaning, and other jargon, understand and follow simple commands, point to 1 or 2 body parts, walk well, stoop, and recover, crawl up stairs or use a cup.</p> <p>Vital Signs: Height 29 in. Weight: 26 lb 8 oz, BMI: 22.15.</p> <p>Physical Exam General: Alert 15 month old male in no acute distress and interactive. Head: Microcephalic Fontanelles normal. Eyes: Retinal reflex bilaterally. Eyes closed most of the time. Nystagmus present bilaterally. Neuro: Unable to sit up or stand on his own. Lower extremities feel hypertonic. Has 3 beat clonus with bilateral legs.</p> <p>Assessment: History of Left otitis media Well child visit.</p>	SPM-99-AH- SPM-102-AH

DATE	FACILITY/ PROVIDER	MEDICAL EVENTS	BATES REF
		<p>Microcephaly Spastic quadriplegia Hypertonia Non intractable epilepsy without status epilepticus, unspecified epilepsy type.</p> <p>Orders: Counseling for recommended immunizations completed. Vaccines given at this time: DTAP, HIB, Prevnar 13, Flu vaccine (when available) Follow up for 18 Month Well Child Check for second Hep A #2.</p>	
02/09/YYYY	Provider/Hospital Name	<p>Neurology Follow-up Visit:</p> <p>History of present illness: Patient returns for followup of epilepsy, microcephaly, severe global developmental delays, spastic quadriplegia. He is here with foster parents.</p> <p>They report he is doing better on Topiramate versus the Depakote. He is more alert and awake and appetite has slowly increase in his back to his baseline. Initially, appetite decreased with the Topiramate. He continues to have one to two episodes of twitching during the day and more on days when he is with his mother, per their report. He had no convulsions.</p> <p>There is a note in his chart from children's hospital Philadelphia ophthalmology reporting that it per their exam he is blind in both eyes. Parents report he will try and focus on their faces and others faces. He turns head to voice, smiles and is "noisy" when excited.</p> <p>He continues to receive early intervention services.</p> <p>Physical examination: On neurological examination, the patient was sleeping but when awake, he did not track visually. He made sounds intermittently. He did not smile. Tongue was midline without fasciculations. Gag is present.</p> <p>On motor examination, truncal hypotonia was noted. Increased muscle tone noted all extremities Cortical thumbs are noted. There is no head lag on traction. He had no tremor or titubation. He did not bring his hands to mouth or midline. He cannot hold his head up of the exam table when placed prone. He did not sit independently. He made no attempts to roll over when on his back or his belly. Lateral prop and parachute reflexes are absent.</p> <p>He did not reach for objects. Sensation was intact to light touch. Reflexes are 2+ bilaterally in the upper and lower extremities and plantars were equivocal bilaterally. Gait is not applicable.</p>	WPN-53-AH- WPN-57-AH

DATE	FACILITY/ PROVIDER	MEDICAL EVENTS	BATES REF
		<p>Assessment: Spastic quadriplegia History of Behind on immunizations; Resolved Microcephaly Nonintractable epilepsy without status epilepticus, unspecified epilepsy type Abnormal finding on MRI of brain; diffuse cerebral ischemic changes. Blind in both eyes</p> <p>Orders: He is doing well on the Topiramate. I will make a small dose increase in the Topiramate and try and change this to a compound that you can get at the Medicine Shop on S. Queen St. I would like him to take 30 mg's every 12 hours. Please return in 4 months for follow up. Continue with Early Intervention services.</p>	
03/27/YYYY	Provider/Hospital Name	<p>Pediatric Follow-up Visit:</p> <p>Chief Complaint: 18 Month Well Patient is now eating pureed foods Foster mother expressed concerns for patient toenails curling.</p> <p>History of present illness: Working closely with PT, just got approved for his trunk support device, should be fitted for it soon. Continues with neuro, PT, OT. Visual therapy soon questionable. Eating large variety pureed fruits and veggies. Does not tolerate milk. Using soy milk, unsure quantity. Regular bowels.</p> <p>Physical Exam: Neuro: Hypertonic</p> <p>Assessment: Spastic quadriplegia Microcephaly Abnormality of shape of nail Well child visit</p> <p>Orders: Referral Podiatry Renew Ranitidine 15 mg/ml Administered: Hepatitis B PED Follow up for 2 year well child check.</p>	SPM-105-AH- SPM-108-AH
04/11/YYYY	Provider/Hospital Name	<p>Pediatric Follow-up Visit:</p> <p>Chief Complaint: Accompanied by: Foster Father</p>	SPM-116-AH- SPM-122-AH

DATE	FACILITY/ PROVIDER	MEDICAL EVENTS	BATES REF
		<p>Immunizations are up to date. Patient here for fever- Tmax 102.5- yesterday Cough- yesterday. Red bump on face- yesterday.</p> <p>History of present illness: Started with a fever 2 days ago Tmax 102.5 F, fever continue today. Has cough as well for the past 2 days, seems to be improving per parents. He has lots of nasal secretions and his breathing sound more noisy than normal. Temp was 99F this morning but now febrile in the office. Has been eating baby food, juice, powerade. Has some vomiting of his baby food today. He has a red blotchy rash on his body. He has been taking his atrovent and flonase for his asthma and chronic lung disease. He has been taking his Albuterol 1-2 times a day to help with his cough.</p> <p>Physical Exam: Vital Signs: Weight: 30 lb 1 oz ; 0-24 Weight Percentile 97%</p> <p>Constitutional: Gross globally delayed boy with lots of nasal secretions and tachypnea. Head: Microcephalic Skin: Fine erythematous papular rash on his face, chest, abdomen and back Nose: Moderate nasal congestion and inflammation Respiratory: Transmitted upper airway noises, good air movement with expiratory wheezes heard bilaterally, tachypnea with subcostal retractions, no rales or rhonchi. Neuro: Grossly developmentally delayed, hypotonia and spastic extremities with little spontaneous movement of all 4 extremities.</p> <p>Albuterol administered in the office: Improvement in tachypnea, no retractions, good air movement bilaterally but still with scattered wheezes bilaterally, very course rhonchorous upper airway noises.</p> <p>Assessment: Spastic quadriplegia. Nasal congestion Chronic lung disease Mild persistent asthma Ineffective airway clearance in child Dysphagia Fever Cough Wheezing.</p> <p>Orders: Administered: Albuterol Sulfate (2.5 mg/3 ml) 0.083%</p>	

DATE	FACILITY/ PROVIDER	MEDICAL EVENTS	BATES REF
		<p>X-ray chest 2 views PA and lateral Respiratory viral detection panel Labs ordered</p> <p>Plan: Patient has fever along with wheezing, tachypnea and retractions. He did respond to Albuterol well. Given the history of vomiting and history of dysphagia, concern for aspiration pneumonia. A chest x-ray was obtained and indicated no infiltrates. Patient was treated for a viral exacerbation of his asthma and chronic lung disease with Prednisolone 2 mg/kg/day divided BID for 5 days, albuterol every 4 hours for the next 5 days, he will continue his current airway clearance with Atrovent, Flovent and Glycopyrrolate. Patient had a urine culture obtained to evaluate causes of his fever and the urine culture was negative.</p> <p>Labs obtained were consistent with viral infection. No virus detected on the respiratory viral panel.</p>	
04/11/YYYY	Provider/Hospital Name	<p>X-ray of chest:</p> <p>Indication: Cough and fever; nasal congestion and wheezing; history of cystic fibrosis, cerebral palsy, and epilepsy.</p> <p>Impression: No acute chest disease.</p>	YH-831-AH- YH-832-AH, YH-830-AH
04/11/YYYY	Provider/Hospital Name	<p>Lab report:</p> <p>CRP 7.56 (H)</p>	YH-833-AH, YH-836-AH
04/11/YYYY	Provider/Hospital Name	<p>Respiratory Virus detection panel:</p> <p>Collected date: 04/11/YYYY Source: Nasopharyngeal</p> <p>No virus detected</p>	YH-837-AH
04/14/YYYY	Provider/Hospital Name	<p>Pediatric Follow-up Visit:</p> <p>Chief Complaint: Accompanied by: Mother Father Patient fussier than usual Cough Congestion Duration: 5 Days</p> <p>History of present illness: Here with mom and dad for follow up. Patient seemed to be coughing more last night and today, was better on the car ride to the office. Per Mom, she noted that when spring started, his cough/fussiness seemed to have increased. Voiding/stooling</p>	SPM-123-AH- SPM-129-AH

DATE	FACILITY/ PROVIDER	MEDICAL EVENTS	BATES REF
		<p>normally.</p> <p>Vitals: Weight: 28 lb 2.5 oz ; 0-24 Weight Percentile 89%</p> <p>Constitutional: Alert, Crying but consolable. Nose: Clear rhinorrhea. +3 turbinates.</p> <p>Assessment: Cough Fussy child.</p> <p>Orders: Possibility of Viral illness vs Allergies. - Try doing Zyrtec 2.5 ml 2x a day - Continue current medicines at home. - Labs are otherwise negative except for mildly elevated CRF and absolute monocyte count which can indicate viral illness. - Follow up as needed</p>	
05/24/YYYY	Provider/Hospital Name	<p>Pediatric Follow-up Visit:</p> <p>Chief Complaint: Accompanied by: Foster Mother, Brother Immunizations are up to date. Here for cough, congestion, seems to have left ear pain Duration: 2 days.</p> <p>History of present illness: Patient here today for evaluation of ear pain. Symptoms started yesterday. Overall doing about the same. Still feeding well, takes food by mouth. Still drinking well. Still making several wet diapers- has had about 3 today.</p> <p>Overall just seems more irritable. Also with congestion (baseline). Here today with foster mother. Has been in Foster Mom's care for past 15 months.</p> <p>Assessment: Acute right otitis media Nasal congestion Viral respiratory illness.</p> <p>Orders: Amoxicillin 400 mg/5 ml - Take 7.5 ml twice daily</p>	SPM-130-AH- SPM-133-AH
05/25/YYYY	Provider/Hospital Name	<p>Pediatric Follow-up Visit:</p> <p>History of present illness: Patient is here today for follow up of congestion, ear infection. Here today with Dad. Taking Amoxicillin and tolerating well. Congestion</p>	SPM-134-AH- SPM-137-AH

DATE	FACILITY/ PROVIDER	MEDICAL EVENTS	BATES REF
		<p>seems to be better. Congestion present.</p> <p>Physical exam: General: Alert 20 month old male in no acute distress and interactive. Head: Normocephalic. Eyes: Retinal reflex bilaterally. Follows objects well. EOM intact and conjugate. Left TM: Dull light reflex, ring of purulent fluid erythema Right TM: +light reflex, TM pearly grey Nose: Nares patent.</p> <p>Assessment: Nasal congestion URI (upper respiratory infection)</p> <p>Orders Continue Amoxicillin for right ear infection. Please keep using Flovent puff two times daily Please keep using Albuterol 1 neb every 3-4 hours (or use 3 puffs of Albuterol inhaler every 3 hours)</p>	
05/30/YYYY	Provider/Hospital Name	<p>Neurology Follow-up Visit:</p> <p>Chief Complaint: Patient is a 20 month old male returning for follow-up for history of unit of sepsis complicated by seizures, spastic quadriplegia, microcephaly, global developmental delays.</p> <p>History of present illness: Patient returns for follow up. He is here with his Foster mother and father.</p> <p>They report he is starting to smile socially. He will hold a ball in his hand and cuts placed there. He is receiving E. stem to help with swallowing. He continues receiving numerous early intervention services including speech, PT, OT, special instruction, E. stim.</p> <p>He was seen by pulmonology and had a sleep study that showed mild obstructive sleep apnea and consideration will be given and his older for a tonsillectomy. He is currently on glycopyrolate due to increased oral secretions and his inability to effectively candled them. They do report he is doing much better since starting this medication. He rarely drools. He does not appear to have any cough or choking episodes. They are giving him water and he tolerates it without thickening.</p> <p>They report he continues to have one or two at episodes of a rapid myoclonic jerks that occur each week. They have otherwise not noted any lip smacking or increase activity concerning of seizure. They feel he is tolerating his medications well without side effects. Appetite remains good. He is sleeping well.</p>	WPN-58-AH- WPN-62-AH

DATE	FACILITY/ PROVIDER	MEDICAL EVENTS	BATES REF
		<p>They recently had a mediation with biological family and a hearing is scheduled for August 30th to terminate parental rights. Biological mother recently had a second male child. CYS is involved. Bio mom sees patient 1.5 hours per week supervised and is otherwise not involved in his care.</p> <p>Vital Signs: Height: 77.5 cm. Weight: 13.20 kg, BMI: 21.98, BSA: 0.50 ; 0-24 Length Percentile 1%; 0-24 Weight percentile 90%</p> <p>Physical exam: He was awake and calm for the majority of the visit. He did move all extremities arms > legs. He made vocalizations and appeared comfortable. He was not in any distress. Vital signs are noted above. He remains overweight.</p> <p>Head was microcephalic, plagiocephalic and atraumatic. Pulses are 2+ bilaterally. Bilateral great toenails are upturned with a thick yellow plaque noted underneath them.</p> <p>On neurological examination, the patient was sleeping but when awake, he did not track visually. He made sounds intermittently. He did not smile. Tongue was midline without fasciculations. Gag is present.</p> <p>On motor examination, truncal hypotonia was noted. Increased muscle tone noted all extremities. Cortical thumbs are noted. He did not bring his hands to mouth are midline. He cannot hold his head up off the exam table when placed prone. He did not sit independently. He made no attempts to roll over when on his back or his belly. Lateral prop and parachute reflexes are absent</p> <p>He did not reach for objects. Sensation was intact to light touch. Reflexes are 2+ bilaterally in the upper and lower extremities and plantars were equivocal bilaterally. Gait is not applicable.</p> <p>Assessment: Dysphagia. Abnormal EEG. Abnormal finding on MRI of brain; diffuse cerebral ischemic changes. Microcephaly. Non intractable epilepsy without status epilepticus, unspecified epilepsy type. Spastic quadriplegia. Blind in both eyes. Neuromuscular scoliosis, thoracolumbar region. Global developmental delay. Chronic static encephalopathy.</p>	

DATE	FACILITY/ PROVIDER	MEDICAL EVENTS	BATES REF
		<p>Child in foster care; maternal, uncle, court ordered custody as of Jan 2016.</p> <p>Orders: Durable Medical Equipment; Gait trainer Continue on to Keppra and Topiramate at current doses. I will speak with the Medicine Shoppe to see if they can compound Lamotrigine for him to add to his medication regimen since he continued to have myoclonic jerks 1-2 times per week.</p> <p>We will call you later this week to let you know if insurance will approve this. Please continue with all therapies and I will see him back in 4 months.</p>	
07/06/YYYY	Provider/Hospital Name	<p>Pediatric Follow-up Visit:</p> <p>Chief Complaint: Swollen Tear Duct.</p> <p>Vital Signs: Weight: 27 lb 9 oz; 0-24 Weight Percentile 72%</p> <p>Assessment: Eyelid cellulitis, left</p> <p>Orders: Cephalexin 250 mg/5ml Oral Suspension Reconstituted; Take 3.5 ml Every twelve hours.</p>	SPM-138-AH- SPM-141-AH
08/15/YYYY	Provider/Hospital Name	<p>Pediatric Follow-up Visit:</p> <p>Chief Complaint: Rash on Hand</p> <p>Assessment: Herpetic whitlow.</p> <p>Orders: Acyclovir 200 mg/5ml Oral Suspension; Take 5 ml every 8 hours.</p>	SPM-142-AH- SPM-145-AH
09/12/YYYY	Provider/Hospital Name	<p>Lab report:</p> <p>Vitamin D 22</p>	YH-841-AH, YH-840-AH
09/29/YYYY	Provider/Hospital Name	<p>Pediatric Follow-up Visit:</p> <p>Chief Complaint: Here for 2 year well visit Accompanied by. Foster Mother, Father, Brother</p> <p>Development:</p> <p>Communication: Patient is blind and nonverbal. He does respond to his mother's voice and sounds. Communicating</p>	SPM-146-AH- SPM-153-AH

DATE	FACILITY/ PROVIDER	MEDICAL EVENTS	BATES REF
		<p>through making noises and facial cues. He does respond to pain.</p> <p>Motor: Non ambulatory. Poor neck and head control. Does not sit upright without assistance. Sits upright in stroller. Has stroller/WC combo. Working on getting gait trainer.</p> <p>Neuro: Followed by WS Pediatric Neurology Abnormal EEG showing generalized epilepsy Static encephalopathy, microcephaly. Seizures currently well controlled on Keppra and Toprimate. Ativan for rescue. Seen at NSU last year for microcephaly no interventions were recommended- Discharged from their care.</p> <p>Ortho: At risk for hip subluxation and NM scoliosis- has not had x-rays completed. Has not been seen by Peds ortho.</p> <p>Vital Signs: Height: 30 in. Weight: 27 lb 15 oz, BMI; 21.82.</p> <p>Physical Exam: General: 24 month old male in no acute distress. Patient does not make eye contact Grimaces during exam on occasion. Does not sit upright without assistance. Head: Microcephalic, poor head and neck control. Neuro: Hypertonia noted to bilateral upper and lower extremities. Poor head control. Does not sit upright unassisted. Left UE: Moderate contracture noted at elbow, extremity is passively fully extended. Right UE: Moderate contracture noted at elbow, extremity is passively fully extended. LLE: contracture noted at hamstring, but extremity is passively fully extended. RLE: contracture noted at hamstring, but extremity is passively fully extended. No purposeful movement of bilateral upper or lower extremities. No pain with ROM of bilateral hips, leg lengths are equal, skin is intact.</p> <p>Assessment: Global developmental delay Chronic lung disease</p>	

DATE	FACILITY/ PROVIDER	MEDICAL EVENTS	BATES REF
		<p>Low vitamin D level. HIE (hypoxic-ischemic encephalopathy).</p> <p>Orders: Discontinue Acyclovir 200 mg/5ml Oral Suspension. Discontinue Cephalexin 250 mg/5ml Oral Suspension Reconstituted. VIT D 25, Vitamin D 25 total, (Vit D 25); Requested for: 29 Sep 2017. Vitamin D3 2000 unit Oral Capsule Durable Medical Equipment; please fit and mold for custom Bilateral knee immobilizers to be worn at night time with AFOs. Administered: Flulaval Quadrivalent 0.5 ml</p> <p>Please follow up in 6 months for next WCC.</p>	
10/05/YYYY	Provider/Hospital Name	<p>Neurology Follow-up Visit:</p> <p>Chief Complaint: Patient is a 2 year old male hers in follow up for epilepsy, spastic quadriplegia, neuromuscular scoliosis, encephalopathy.</p> <p>Patient returns for follow-up of epilepsy, microcephaly, static encephalopathy and comorbid diagnoses. He is here with his foster parents. They report seizures were quiet for several weeks and more recently she has noticed very brief periods of eye rolling. It happens 2-3 times per day lasting a few seconds. They are not sing anymore myoclonic jerking.</p> <p>He lost a lithe bit of weight over the past couple of months but is slowly starting to regain. He continues to take all food by mouth and they deny he has any choking or swallowing difficulties. He continues to receive numerous services through early intervention.</p> <p>Arm and leg muscles are tight and this is increasing over the past several months. They are actively working with physical therapy to help with hypertonia. They continue to use E-stim to help coordinate swallowing.</p> <p>Mother reports he is making more sounds and turns head to their voices.</p> <p>Per their report mother and father terminated their parental rights and foster parents are pursuing adoption.</p> <p>Assessment: Neuromuscular scoliosis, thoracolumbar region. Abnormal EEG. Abnormal finding on MRI of brain; diffuse cerebral ischemic changes. Microcephaly. Spastic quadriplegia. Blind in both eyes.</p>	WPN-63-AH- WPN-67-AH

DATE	FACILITY/ PROVIDER	MEDICAL EVENTS	BATES REF
		<p>Chronic lung disease. Dysphagia. Global developmental delay. Chronic static encephalopathy. HIE (hypoxic-ischemic encephalopathy).</p> <p>Orders: Increase the Keppra to 3.5 ml every 12 hours starting tonight. Continue on same dose of Topiramate. Continue with all therapies and services. Return in 6 months. Renew Glycopyrrolate 1 mg/5ml Injection Renew Compound; Topiramate 60 mg's (5ml) Renew Levetiracetam 100 mg/ml Oral</p>	
02/05/YYYY	Provider/Hospital Name	<p>ER visit for fever:</p> <p>Chief Complaint: Fever. Fussiness, Vomiting this AM, No diarrhea, Accompanied by Foster Mother.</p> <p>Diagnosis: Viral syndrome Spastic quadriplegia (CMS/HCC) Hypoxic ischemic encephalopathy, unspecified severity Non-intractable vomiting, presence of nausea Not specified, unspecified vomiting type</p> <p>Plan: He had one episode of throwing up but not since and is eating as usual. His exam is normal. He is acting happier today than yesterday. He should only continue to improve.</p>	SPM-154-AH- SPM-158-AH
02/07/YYYY	Provider/Hospital Name	<p>ER visit for upper respiratory symptoms:</p> <p>Chief complaint: Altered mental status</p> <p>Diagnosis: Viral syndrome</p> <p>Medical decision making: Patient on examination is well-appearing, nontoxic, playful with mother, consolable by mother, good urine output, physical examination benign. Patient is well-appearing on exam, patient afebrile, patient still eating drinking appropriately. Mother states patient has it in improving since arrival to emergency department. Mother feels comfortable taking patient home, follow up with pediatrician as needed.</p>	YH-772-AH- YH-781-AH, YH-782-AH- YH-786-AH, YH-791-AH- YH-795-AH
03/28/YYYY	Provider/Hospital Name	<p>Pediatric Follow-up Visit:</p> <p>Chief Complaint:</p>	SPM-159-AH- SPM-166-AH

DATE	FACILITY/ PROVIDER	MEDICAL EVENTS	BATES REF
		<p>Here for 2 year well visit Accompanied by. Foster Mother, Father, Brother</p> <p>Development: Patient is currently enrolled in EIS. He is working with PT and OT services. These therapists come to the home 2 times monthly to work with patient. Patient has made improvements since last WCC. He is now able to sit upright with minimal assistance-with better head and trunk control. He is working on tummy time on a regular basis and this has helped with core strengthening. Mom is planning on transitioning him to LIU next year. She thinks that he will do well with preschool.</p> <p>Motor: Does take steps in gait trainer with assistance.</p> <p>Ortho: Has not been seen by Peds ortho. Referral in place.</p> <p>Vital Signs: Height: 0.8 m. Weight: 13.2 kg</p> <p>Physical Exam: Constitutional: Patient is awake and responds to pain during exam. He is able to sit upright with assistance. He has poor head and neck control. Head: Microcephaly is noted. Left TM: wax removed with curette, visible TM is pearly grey without erythema. Right TM: wax removed with curette, there is mild bleeding of the TM following procedure, visible TM is pearly grey without erythema. Musculoskeletal: There are contractures noted to the bilateral upper and lower extremities. There are hip adductor contractures. There is no pain with ROM of hips. The spine clinically appears straight. Neuro: Hypertonia is noted with clonus.</p> <p>Assessment/Plan: 1. Encounter for well child examination with abnormal findings 2. Hypoxic ischemic encephalopathy 3. Global developmental delay</p> <p>Patient is growing well. His weight and growth has been stable since last visit. As long as weight gain remains stable and he takes food by mouth I do not see need to refer to GI or Peds Surgery. Continue follow up with nutrition. Continue with EIS and transition to LIU for preschool</p> <p>4. Viral URI and nasal congestion</p>	

DATE	FACILITY/ PROVIDER	MEDICAL EVENTS	BATES REF
		<p>5. Ineffective airway clearance in child</p> <p>6. Neuromuscular scoliosis, thoracolumbar region Risk for hip subluxation, lower extremity contractures, and equipment needs. Follow up with rehab doctors at Hershey as planned. You need to see ortho as well. He needs to have his hips and spine evaluated. Continue with night time knee immobilizers. Continue with AFOs to prevent contractures.</p> <p>7. Low vitamin D level Get vitamin D level and lead level- I will call with results. This will determine need to continue therapy with vitamin D supplement. -Vitamin D 1,25 dihydroxy; Future</p> <p>8. Lead Screening</p> <p>9. Blind in both eyes Follow up with CHOP Optho as recommended.</p> <p>10. Penile Adhesion Ambulatory referral to Pediatric Urology; Future Start using betamethasone ointment.</p> <p>Follow up in 6 months for next Well Child Check</p>	
04/05/YYYY	Provider/Hospital Name	<p>Neurology Follow-up Visit:</p> <p>History of Present Illness: Patient is a 2 years old 6 month not yet handed male with a history of hypoxic ischemic event, neonatal sepsis, microcephaly, and associated abnormalities. He has focal and generalized epilepsy.</p> <p>They report no seizures for several weeks. They would like to wean the Levetiracetam if possible. He has had no recent hospitalizations or new medical problems. They feel he is tolerating the Lamotrigine and Trileptal without difficulty. He needs to receive numerous therapies through early intervention. They feel he is trying to fix and focus more frequently than in the past. They feel he is doing better with his head control and is tolerating standing in a gait trainer for up to 30 minutes at a time.</p> <p>Weight: 13.8 kg</p> <p>Physical exam: On neurological examination, the patient was alert but minimally active. Eyes are roving but he did fix briefly. He did not track. He did respond and try and look at my ophthalmoscope. I was unable to visualize fundi. There was no nystagmus. He did not smile. Palate rose symmetrically. Tongue was midline without fasciculations.</p>	WPN-68-AH- WPN-72-AH

DATE	FACILITY/ PROVIDER	MEDICAL EVENTS	BATES REF
		<p>On motor examination, tone is increased. There is normal muscle bulk. Patient was not able to complete strength testing. Purposeful movements were minimal. He did not bring hands to midline or mouth, reach for toys, Attempt to get on hands/knees or support himself when prone. He can barely lift head off of exam table. There was no abnormal motor movements.</p> <p>There was no tremor or titubation. Sensation was intact to light touch. Reflexes are 3+ bilaterally in the upper and lower extremities and plantars were upgoing. Gait not applicable.</p> <p>Assessment and plan:</p> <ol style="list-style-type: none"> 1. Abnormal EEG- Lamotrigine (Lamictal) 5 mg tablet, chewable dispersible chewable tablet 2. Chronic static encephalopathy 3. Hypoxic ischemic encephalopathy, unspecified severity 4. Other epilepsy without status epilepticus, not intractable 5. Spastic quadriplegia 6. Dysphagia, unspecified type 7. Hypertonia 8. Microcephaly 9. Neuromuscular scoliosis, thoracolumbar region 10. Blind in both eyes 11. Global developmental delay 12. Abnormal finding on MRI of brain <p>Growth is appropriate. He remains microcephalic significant plagiocephaly/head shape. Foster parents feels seizures are under good control. He exhibits occasional jerking of his arms but is not repetitive. They do not feel this is seizure.</p> <p>We will attempt to wean the Levetiracetam. He will continue on Trileptal and Lamotrigine at same doses. He will continue with early intervention services. We will follow-up in 6 months.</p>	
04/23/YYYY	Provider/Hospital Name	<p>Pediatric Follow-up Visit:</p> <p>Chief Complaint: Cough and congestion, no fever, here with mom.</p> <p>Assessment/plan:</p> <ol style="list-style-type: none"> 1. Cough 2. Viral Respiratory illness <p>Duoneb (in nebulizer machine) every 3-4 hours. Flovent 4 puffs 2 times per day (wash mouth out after use). Atrovent 2 puffs 2 times per day. Flonase nasal spray as prescribed.</p> <ol style="list-style-type: none"> 3. Mild hypoxic-ischemic encephalopathy - Ambulatory referral to Physical Therapy, Orthopedic Surgery; Future 	SPM-167-AH- SPM-171-AH, WPN-108-AH- WPN-109-AH

DATE	FACILITY/ PROVIDER	MEDICAL EVENTS	BATES REF
05/06/YYYY	Provider/Hospital Name	<p>Pediatric Follow-up Visit:</p> <p>Chief complaint: Fussy for 3 days here with guardian. Cough.</p> <p>Vitals: Weight: 14.2 kg</p> <p>Diagnosis and Plan:</p> <ol style="list-style-type: none"> 1. Allergic rhinitis, unspecified seasonality unspecified trigger 2. Hypoxic ischemic encephalopathy, unspecified severity 3. Spastic quadriplegia 4. Chronic lung disease. <p>Start flonase, one spray each nostril once daily. Continue Zyrtec.</p>	SPM-172-AH- SPM-176-AH
06/21/YYYY	Provider/Hospital Name	<p>Neurology Follow-up Visit:</p> <p>Patient seen for urgent follow-up on 6/21/YYYY. Patient is a 2 years 9 month old male with a non-progressive encephalopathy and associated problems secondary to hypoxic ischemic encephalopathy in the newborn.</p> <p>Patient returns for follow-up. Since his last evaluation, he tapered off the Levetiracetam. His adoptive mother noted over the last few days that there has been an increase of myoclonic jerks occur throughout the day. She reports no other seizure-like episodes. These do not occur in sleep. He is tolerating his feeds. She thinks that they are worse since the Levetiracetam was discontinued. She is uncertain as to which medication has had the biggest impact on seizure control. There has been no recent EEG. He is eating by mouth and tolerating feeds.</p> <p>Physical exam: On neurological examination, he was alert. His profound intellectual disabilities. Cranial nerves reveal pupils to be equal and reactive. I could not assess visual fields and I could not visualize fundi. Ductions were full spontaneously and there was no nystagmus or ptosis. There is a roving quality to his eye movements. Grimace was symmetric. Tongue was midline without fasciculations.</p> <p>On motor examination, he had markedly increased appendicular tone in all 4 extremities with bilateral cortical thumbs. Truncal tone was normal to slightly increased. There is a paucity of spontaneous movements and movements tended to be en bloc. There were no abnormal motor movements. Coordination/gait not applicable. Reflexes were 3+ bilaterally in the upper and lower extremities. Toes were neither up or downgoing.</p>	WPN-73-AH- WPN-77-AH, YH-789-AH- YH-790-AH

DATE	FACILITY/ PROVIDER	MEDICAL EVENTS	BATES REF
		<p>Follow-up today: We saw him because you are noticing an increase in total body myoclonic jerks. Reviewing his EEGs, he had myoclonic jerks in the past which were associated with abnormalities on the EEG. We think these have increased since the tapering of the Levetiracetam. We discussed that sometimes medications like Oxcarbazepine can increase the myoclonic jerks. Also, children with his type of brain problems can have myoclonic jerks that are non-seizure-like. In the short-term, I would like to obtain an EEG and I would like to taper and discontinue the Oxcarbazepine. We will optimize the Lamotrigine. If jerks increase, we can consider other medications. Let us taper the Oxcarbazepine as follows: 6/21- 25: 3 ml twice a day 6/26-30: 2 ml twice a day 7/1-5: 1 ml twice a day 7/6 and after: Discontinue Oxcarbazepine</p> <p>Please increase the Lamotrigine to 15 mg in the morning and 25 mg at night the next week and then increase to 25 mg twice daily. I sent a prescription for the 25 mg dispersible tablets to the pharmacy.</p> <p>We will give you a call in about 3 weeks for an update and also will call you with results of the EEG. If the myoclonic jerks persist, we might consider other medications.</p> <p>Patient will return to the clinic in 2 months for follow-up or sooner as needed.</p>	
06/28/YYYY	Provider/Hospital Name	<p>EEG report:</p> <p>History: 2 year old boy with history of perinatal hypoxic ischemic encephalopathy and neonatal seizures now with myoclonic jerks.</p> <p>Impression: This is an abnormal tracing in the awake and drowsy states due to the following:</p> <ol style="list-style-type: none"> 1. Background slowing for age 2. Relative suppression of normal rhythms over the parietal and occipital regions bilaterally in wakefulness with absence of a dominant occipital rhythm. 3. Myoclonic jerk associated with a single generalized spike wave discharge consistent with a myoclonic seizure. 	YH-788-AH- YH-789-AH
08/06/YYYY	Provider/Hospital Name	<p>Pediatric Follow-up Visit:</p> <p>Chief Complaint: Bump on right eye. Bump has gone down, area is red now, here with mom and dad</p> <p>Assessment/plan: 1. Hordeolum externum right lower eyelid - This should resolve over the next several days. Do cold compresses or warm compresses</p>	SPM-177-AH- SPM-181-AH

DATE	FACILITY/ PROVIDER	MEDICAL EVENTS	BATES REF
		<p>over the eyes. Use Vaseline over area of irritation.</p> <p>2. Insect bite, initial encounter - Use zyrtec 2.5 ml.</p>	
08/29/YYYY	Provider/Hospital Name	<p>Neurology Follow-up Visit:</p> <p>History of Present Illness: Patient is here with his mother. He was officially adopted last month and family could not be any more excited about this.</p> <p>Mother reports since discontinuation of Oxcarbazepine the myoclonic jerks have decreased but he continues to have more than he was several months ago. Sometimes she sees several of them in an hour, and other times none. She does note a decrease in appetite over the past several months since discontinuing the Oxcarbazepine. She is wondering if this may be causing him not to be as happy as he was previously or is this secondary to seizures. She does not notice myoclonic jerks when he is sleeping. She reports he is trying to roll from his side to his belly lately she feels he is better able to hold his head up when he was a few months ago.</p> <p>She is requesting a prescription for bilateral hand splints be faxed to Lawall orthotics at Hershey.</p> <p>Assessment and plan:</p> <ol style="list-style-type: none"> 1. Intractable epilepsy with both generalized and focal features - Lamotrigine (Lamictal) 25 mg tablet. 2. Abnormal EEG 3. Central visual impairment 4. Chronic static encephalopathy 5. Global developmental delay 6. Microcephaly. 7. Microencephaly. 8. Neuromuscular scoliosis, thoracolumbar region 9. Spastic quadriplegia <p>His exam today is stable with the exception of 2 pound weight loss since May and 4 myoclonic jerks witnessed today. The Oxcarbazepine was discontinued and this may have been increasing his appetite/food intake.</p> <p>He continues to have episodes of myoclonic Jerks. Most recent EEG was completed June 28, 2018 and read by Dr. Barron.</p> <p>I increased the Lamotrigine to 37.5 mg twice daily and he will continue on 250 mg of Levetiracetam twice daily.</p> <p>I've asked mother to contact me within 1-2 weeks to see if the increase in Lamotrigine provides any decrease in myoclonic jerks. If not, we can consider the ketogenic diet, Zonisamide, or Clobazam.</p>	WPN-78-AH- WPN-82-AH

DATE	FACILITY/ PROVIDER	MEDICAL EVENTS	BATES REF
09/20/YYYY	Provider/Hospital Name	<p>Pediatric Follow-up Visit:</p> <p>Chief Complaint Well Child- 3 year well, here with mom and dad</p> <p>Developmental: Communicating: He does respond to his mother's voice and sounds, communicating through making noises and facial cues. He does respond to pain.</p> <p>Neuro: Followed by WS Pediatric Neurology. Abnormal BEG showing generalized epilepsy. Static encephalopathy, microcephaly. Took him off Keppra- seizures worsened, went back on. Now working on getting seizure controlled with Keppra and Lamictal. Ativan for rescue. Has not needed to use. Going to information session on using medical marijuana to help with seizure control.</p> <p>Assessment/Plan:</p> <ol style="list-style-type: none"> 1. Encounter for well child examination with abnormal findings 2. Hypoxic ischemic encephalopathy 3. Global developmental delay <p>Patient is growing and developing well. Keep feeding as you are. Weight is trending down. Continue with LIU for preschool, PT/OT needs.</p> <ol style="list-style-type: none"> 4. Ineffective airway clearance in child: Follow up with pulmonary as planned. 5. Neuromuscular scoliosis, thoracolumbar region: Risk for hip subluxation, lower extremity contractures, and equipment needs. Follow up in 1 year with Ortho. We will continue to manage rehab needs locally. Saw Rehab at HMC, but not much added. Waiting for NuMotion to call back- will try to coordinate equipment eval in our office. Continue with night time knee immobilizers. Continue with AFOs to prevent contractures. 6. High vitamin D level: Last vitamin D level was high at 106. Needs repeat level drawn (ordered)- I will call with results. - Vitamin D 1,25 dihydroxy 7. Lead Screening: Last lead level obtained in April 2018 and was normal. Do not need to repeat. 8. Blind in both eyes 	SPM-182-AH- SPM-189-AH

DATE	FACILITY/ PROVIDER	MEDICAL EVENTS	BATES REF
		<p>Follow up with CHOP Optho as recommended. New referral placed today.</p> <p>9. Penile Adhesion resolved: Continue with Betamethasone as prescribed.</p> <p>Follow up in 6 months for next Well Child Check</p>	
10/19/YYYY	Provider/Hospital Name	<p>Pediatric Follow-up Visit:</p> <p>Chief Complaint: Mouth has a sore area on the roof of his mouth, here with mom.</p> <p>Assessment/plan:</p> <p>1. Mucosal irritation of oral cavity Mouth looks good on exam today. There was a little irritation on the right side of the buccal mucosa. Just keep mouth clean, keep brushing teeth. Tylenol for pain as needed.</p> <p>2. Need for influenza vaccination - Flu Vaccine/Fluzone MDV 36 Mos Up</p>	SPM-190-AH- SPM-199-AH
12/11/YYYY	Provider/Hospital Name	<p>Neurology Follow-up Visit:</p> <p>The patient returns for follow-up. He is currently a 3-year-old boy with a history of a nonprogressive encephalopathy secondary to neonatal sepsis and hypoxic ischemic injury with resultant microcephaly and poorly controlled epilepsy.</p> <p>Since his last evaluation, he continues to have multiple seizures on a daily basis. He typically has multiple myoclonic Jerks and has up to 20 tonic seizures a day lasting a few seconds to a minute. He has had no convulsions. He has failed a variety of anti-seizure medications including currently Levetiracetam and Lamotrigine as well as Valproic acid, Topiramate, Gabapentin, Oxcarbazepine and Phenobarbital.</p> <p>Physical exam: On neurological examination, he was alert. Cranial nerves reveal pupils equal and reactive. I could not assess visual fields and I could not visualize fundi. Ductions were full by observation. Intermittent rapid, horizontal nystagmus was noted. Grimace was symmetric. Tongue was midline.</p> <p>On motor examination, there was truncal hypotonia. Tone was increased in all 4 extremities and there was bilateral cortical fisting. He moves all 4 extremities symmetrically and en bloc. There were no purposeful movements and overall there was a paucity of spontaneous movement. Reflexes were 3+ bilaterally. He is non ambulatory. Coordination could not be assessed.</p> <p>He continues to have seizures despite optimization of his current</p>	WPN-83-AH- WPN-88-AH

DATE	FACILITY/ PROVIDER	MEDICAL EVENTS	BATES REF
		<p>medications. He is failed a variety of other medicines as well. As such, we discussed a trial on Epidiolex-Cannabadiol. This is a recently FDA approved medication for his type of epilepsy. It is not illegal. It is well-tolerated. It is in a liquid formulation.</p> <p>Side effects can include fatigue, drowsiness, diminished appetite and rarely elevation of liver functions. As such, we will need to check liver functions at 1, 3 and 6 months. He had a baseline set of liver functions a few months ago which were normal. It is administered twice daily. We are going to aim for dose of 10 mg/kg but if not effective, we can increase further to dose of 20 mg/kg. It will not interact with the medications he is currently taking. He is not allergic to sesame oil by your report. If he does well, we might try to get rid of 1 of the other medications but he must remain on at least one other medication along with the Cannabadiol. It contains virtually no THC but will turn a drug test positive. It will not cause any psychoactive effects. This medication is obtained through specialty pharmacy. It will be mailed to your house. You will receive a phone call to confirm the address and to confirm an individual who can receive the package. You will have a phone call from A1 800-number. Please answer this call.</p> <p>Please start the medication as follows once you receive it; Week 1: 0.4 mL twice daily Week 2: 0.4 mL in the morning and 0.8 ml at bedtime Weeks 3 and after: 0.8 ml twice a day</p> <p>Let us plan on seeing him back in 4 months. Once again, please let us know when you receive the medication so we can set up reminder call if you to check the liver functions.</p> <p>Assessment and Recommendations: The patient is a 3-year-old boy with a non progressive encephalopathy secondary to hypoxic ischemic encephalopathy with resultant intellectual disabilities, spastic quadriparesis and intractable epilepsy most consistent with Lennox-Gastaut syndrome. He continues to have daily seizures and we discussed strategies for treating them. We will continue his current medications but start him on Epidiolex/cannabadiol. Side effects were reviewed. Further information is in the after visit summary. He will start on 40 mg twice daily and increase to dose of 80 mg twice a day once available. This is 10 mg/kg and can be optimized further to 20 mg/kg. His adoptive mother was in agreement with this plan. Baseline liver functions were normal.</p> <p>Patient will return to the clinic in 6 months for follow-up or sooner as needed.</p>	

Other records (Non-medical):

Authorization (Bates Ref: YH-14-AH- YH-22-AH, YH-851-AH- YH-853-AH, SPM-1-AH-SPM-18-AH)

DATE	FACILITY/ PROVIDER	MEDICAL EVENTS	BATES REF
Blank Pages (Bates Ref: MH-51-CLT, MH-201-AH, MH-21-AH, MH-101-AH-MH-102-AH, MH-125-AH, MH-153-CLT)			
Coding Sheet (Bates Ref: MH-38-CLT, MH-11-AH, MH-147-AH, MH-183-AH)			
Consent (Bates Ref: YH-20-AH- YH-21-AH, MH-236-AH- MH-244-AH, MH-12-AH- MH-20-AH, MH-30-CLT- MH-37-CLT, MH-39-CLT- MH-40-CLT, YH-356-AH- YH-357-AH, YH-768-AH- YH-770-AH, WPR-41-AH- WPR-43-AH, MH-250-AH- MH-253-AH, MH-148-AH- MH-149-AH, MH-176-AH- MH-179-AH, YH-458-AH- YH-459-AH, YH-474-AH, YH-657-AH, YH-742-AH- YH-743-AH, MH-184-AH, MH-215-AH- MH-219-AH, WPR-20-AH- WPR-21-AH)			
Duplicate (Bates Ref: MH-137-AH- MH-138-AH, MH-142-AH, MH-156-CLT, MH-33-AH- MH-35-AH, MH-131-CLT, MH-41-CLT- MH-47-CLT, MH-29-CLT, MH-22-AH- MH-24-AH, MH-25-AH- MH-31-AH, MH-63-CLT- MH-65-CLT, MH-157-CLT- MH-161-CLT, MH-235-AH, MH-49-CLT- MH-50-CLT, MH-103-AH- MH-135-AH, MH-131-CLT- MH-152-CLT, MH-103-AH, YP-6-REF- YP-11-REF, WPN-89-AH- WPN-92-AH, YH-366-AH- YH-367-AH, PN-93-AH- WPN-98-AH, YH-372-AH- YH-374-AH, YH-40-CLT- YH-42-CLT, YH-38-REF- YH-40-REF, MH-35-AH- MH-37-AH, YH-18-REF- YH-19-REF, YH-45-CLT- YH-48-CLT, YH-43-REF- YH-46-REF, MH-103-AH, YH-372-AH, YH-20-CLT, YH-818-AH, YH-824-AH, YH-828-AH, YH-834-AH, YH-838-AH, YH-842-AH, YH-154-AH, MH-128-CLT, YH-23-CLT- YH-39-CLT, YH-3-CLT- YH-9-CLT, YH-11-REF- YH-17-REF, YH-50-CLT- YH-77-CLT, YH-21-REF- YH-37-REF, YH-46-REF- YH-47-REF, YH-40-REF- YH-43-REF, YH-348-AH- YH-349-AH, YH-15-CLT- YH-19-CLT, YH-6-REF- YH-10-REF, MH-260-AH- MH-261-AH, YH-42-CLT- YH-45-CLT, YH-48-CLT- YH-49-CLT, MH-38-AH, YH-19-REF- YH-20-REF, MH-254-AH- MH-257-AH, YH-48-REF- YH-75-REF, YP-15-REF, YH-107-REF, WPN-99-AH- WPN-100-AH, YH-100-REF- YH-102-REF, WPR-47-AH- WPR-52-AH, YH-77-REF- YH-78-REF, YH-543-AH- YH-544-AH, YH-80-REF- YH-83-REF, YH-115-REF- YH-119-REF, YH-103-REF- YH-104-REF, YH-87-REF- YH-93-REF, YH-112-REF- YH-114-REF, YH-586-AH- YH-593-AH, YH-487-AH- YH-493-AH, MH-302-REF- MH-305-REF, MH-305-REF- MH-316-REF, MH-318-REF- MH-321-REF, MH-291-REF- MH-301-REF, YH-798-AH- YH-799-AH, YH-802-AH- YH-804-AH, YH-806-AH- YH-809-AH, YH-814-AH, WPN-101-AH- WPN-103-AH, YH-822-AH- YH-823-AH, YH-825-AH, YH-843-AH, WPN-109-AH- WPN-110-AH, MH-164-CLT- MH-199-CLT, YH-32-AH- YH-33-AH, YH-105-REF- YH-106-REF, YH-829-AH, YH-835-AH, YH-839-AH, YH-94-REF- YH-99-REF, YH-819-AH)			
Fax Sheets (Bates Ref: YH-76-REF, YP-16-REF)			
Legal Documents (Bates Ref: MH-224-AH- MH-227-AH, MH-228-AH- MH-231-AH, YH-844-AH- YH-850-AH)			
Patient's Information (Bates Ref: YH-457-AH, MH-249-AH, MH-145-AH- MH-146-AH, YH-740-AH, MH-180-AH- MH-182-AH, MH-287-REF- MH-290-REF, YH-767-AH, YH-771-AH, YH-787-AH, WPR-33-AH- WPR-37-AH)			
Others (Bates Ref: YH-475-AH- YH-476-AH, YH-741-AH, SPM-19-AH-SPM-20-AH, YP-3-REF- YP-5-REF, WN-4-REF)			
Telephone Conversation (Bates Ref: YH-350-AH- YH-351-AH)			